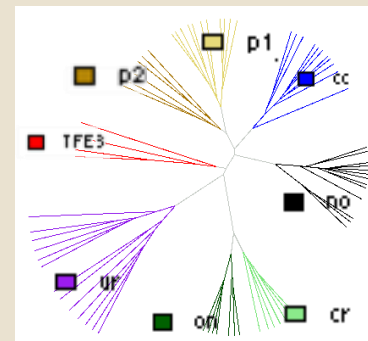



RENAL TUMOURS



Dr Ph Camparo
Centre de Pathologie
Amiens
France

Renal cell tumours

Clear cell renal cell carcinoma	8310/3
Multilocular cystic renal neoplasm of low malignant potential	8316/1
Papillary renal cell carcinoma	8255/1
Hereditary leiomyomatosis and renal cell carcinoma (HLRCC)-associated renal cell carcinoma	8311/3*
Chromophobe renal cell carcinoma	8317/3
Collecting duct carcinoma	8319/3
Renal medullary carcinoma	8510/3
MIT Family translocation carcinomas	8311/3
Succinate dehydrogenase (SDH)-deficient renal carcinoma	8312/3
Mucinous tubular and spindle cell carcinoma	8480/3
Tubulocystic renal cell carcinoma	8316/3
Acquired cystic disease associated renal cell carcinoma	8316/3
Clear cell papillary renal cell carcinoma	8323/1
Renal cell carcinoma, unclassified	8312/3
Papillary adenoma	8260/0
Oncocytoma	8290/0

Metanephric tumours

Metanephric adenoma	8325/0
Metanephric adenofibroma	9013/0
Metanephric stromal tumour	8935/1

Nephroblastic tumours

Nephrogenic rests	
Nephroblastoma	8960/3
Cystic partially differentiated nephroblastoma	8959/1
Paediatric cystic nephroma	8959/0

Mesenchymal tumours***Mesenchymal tumours occurring mainly in children***

Clear cell sarcoma	8964/3
Rhabdoid tumour	8963/3
Congenital mesoblastic nephroma	8960/1
Ossifying renal tumour of infants	8967/0

Mesenchymal tumours occurring mainly in adults

Leiomyosarcoma	8890/3
Angiosarcoma	9120/3
Rhabdomyosarcoma	8900/3
Osteosarcoma	9180/3
Synovial sarcoma	9040/3
Ewing sarcoma / Peripheral neuroectodermal tumour	9260/3
Angiomyolipoma	8860/0
Epithelioid angiomyolipoma	8860/1
Leiomyoma	8890/0
Haemangioma	9120/0
Lymphangioma	9170/0
Haemangioblastoma	9161/1
Juxtaglomerular cell tumour	8361/0
Renomedullary interstitial cell tumour	8966/0
Schwannoma	9560/0
Solitary fibrous tumour	8815/1

Mixed epithelial and mesenchymal tumours

Cystic nephroma	8959/0
Mixed epithelial and stromal tumour	8959/0

Neuroendocrine tumours

Well-differentiated neuroendocrine tumour	8240/3
Large cell neuroendocrine carcinoma	8013/3
Small cell neuroendocrine carcinoma	8041/3
Paraganglioma	8693/1
Pheochromocytoma	8700/0

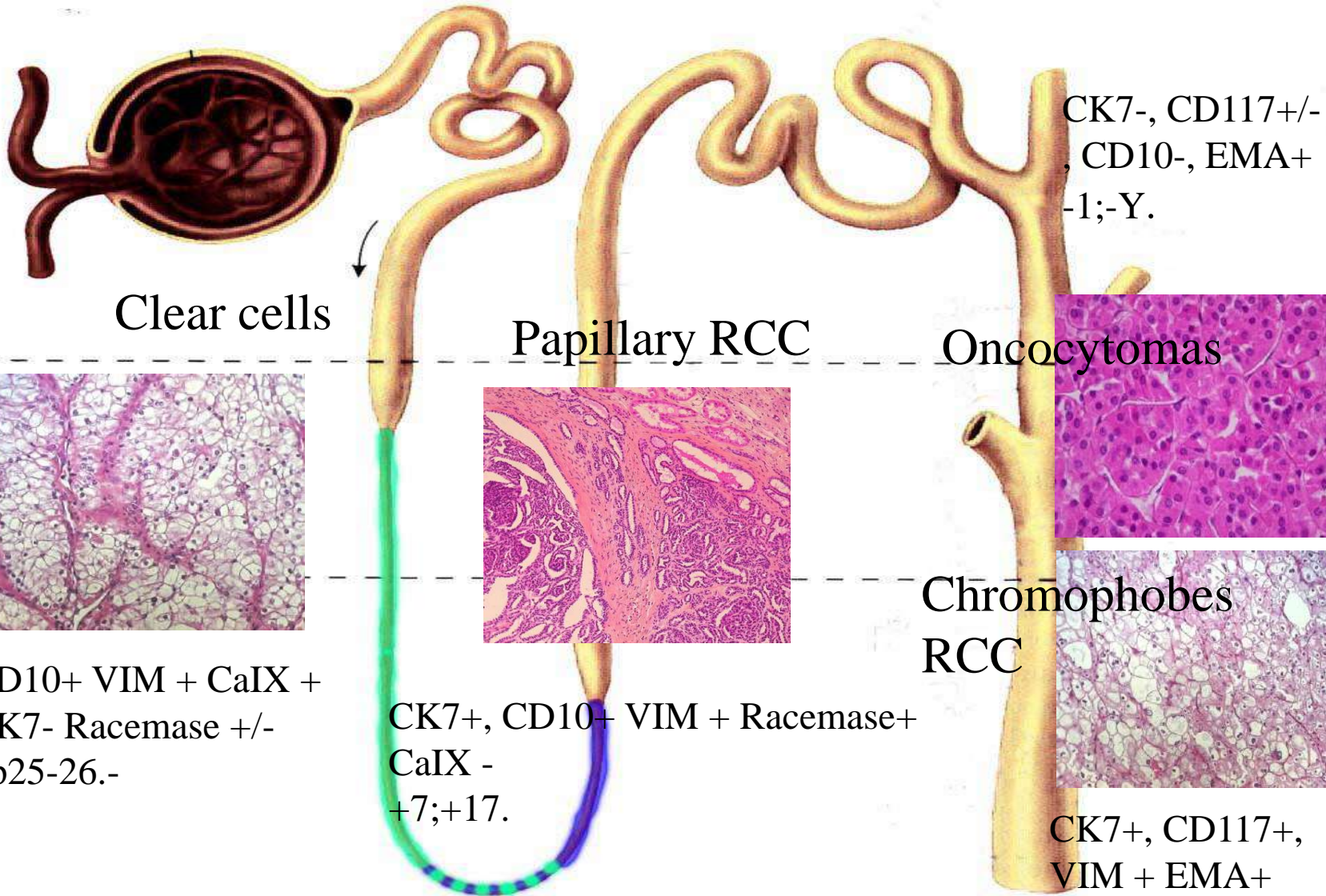
Miscellaneous tumours

Renal haematopoietic neoplasms	
Germ cell tumours	

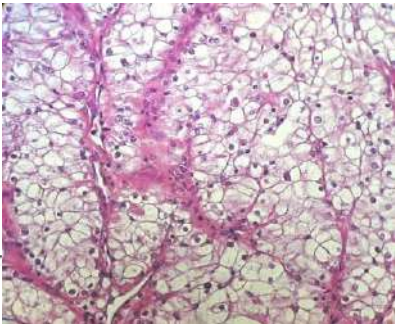
Metastatic tumours

The morphology codes are from the International Classification of Diseases for Oncology (ICD-O) [917A]. Behaviour is coded /0 for benign tumours; /1 for unspecified, borderline, or uncertain behaviour; /2 for carcinoma in situ and grade III intraepithelial neoplasia; and /3 for malignant tumours. The classification is modified from the previous WHO classification [756A], taking into account changes in our understanding of these lesions.

* These new codes were approved by the IARC/WHO Committee for ICD-O.

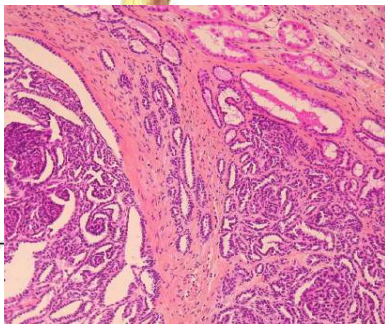


Clear cells



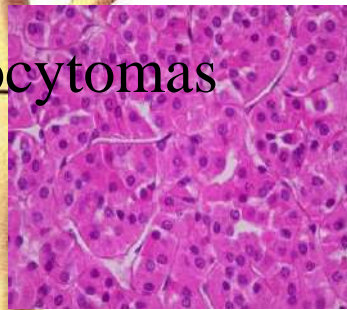
CD10+ VIM + CaIX +
CK7- Racemase +/-
3p25-26.-

Papillary RCC



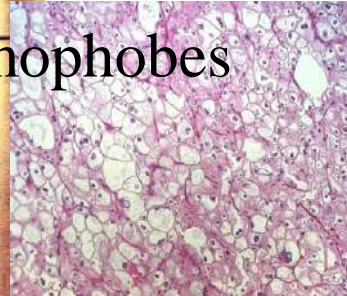
CK7+, CD10+ VIM + Racemase+
CaIX -
+7;+17.

Oncocytomas



CK7-, CD117+/-
CD10-, EMA+
-1;-Y.

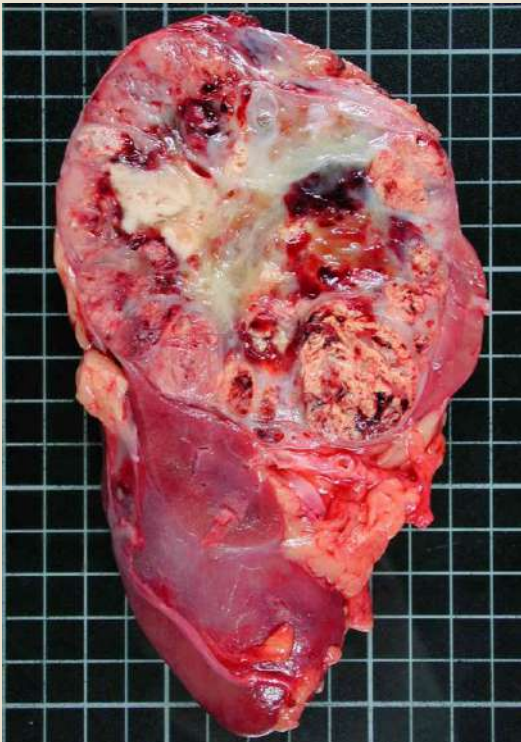
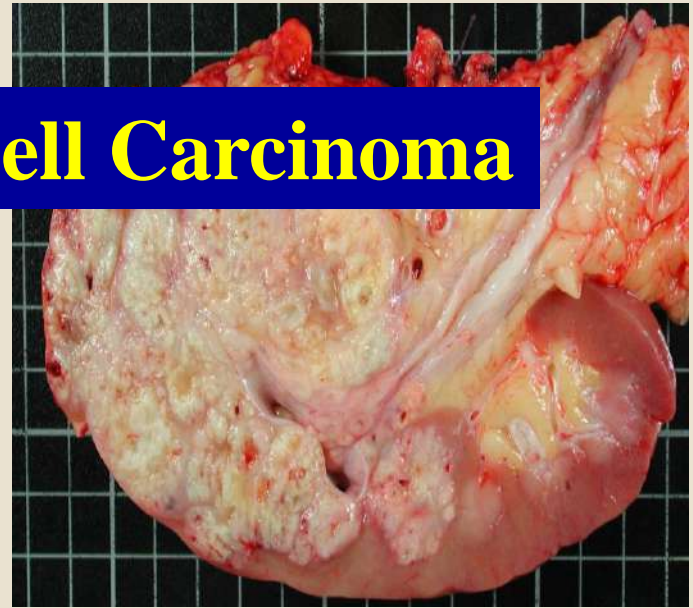
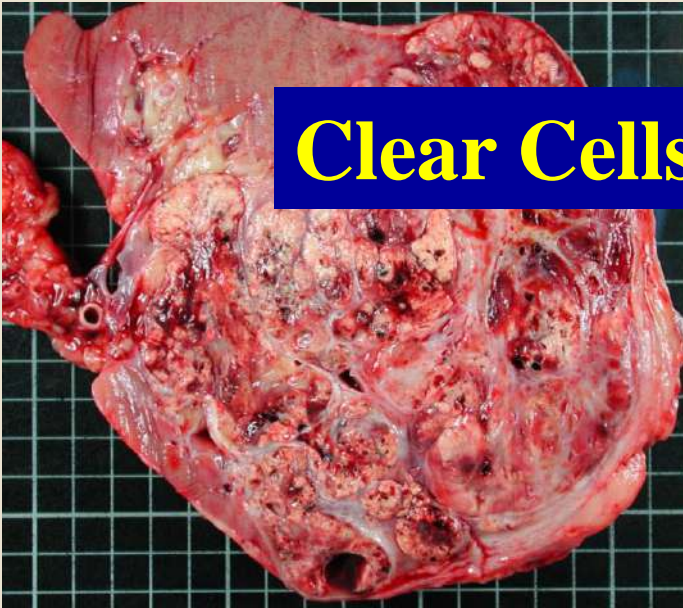Chromophobes
RCC



CK7+, CD117+,
VIM + EMA+
-1;-2;-6;-10;-Y

PAX 8 is supposed to be expressed by all renal cell carcinomas
Not specific (uterine and ovarian tumors)

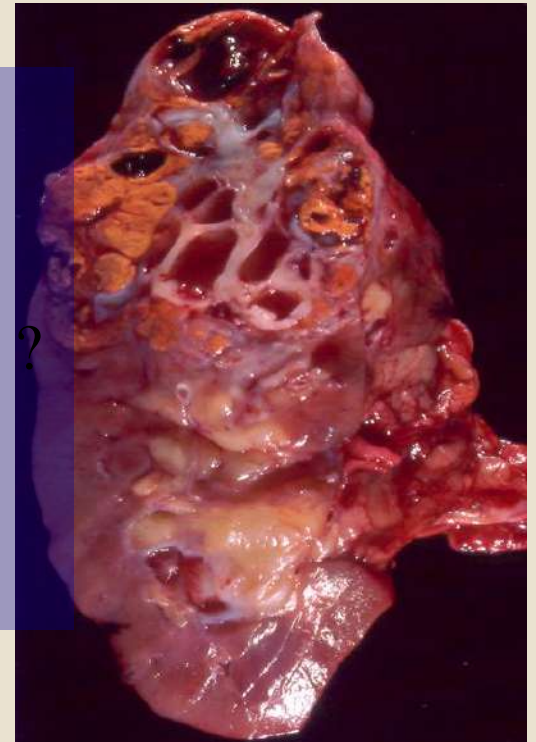
Clear Cells Renal Cell Carcinoma



Modified Fuhrman
Nuclear Grading

Molecular classification ?

Antiangiogenic and
immunotherapies



Clear Cells Renal Cell Carcinoma

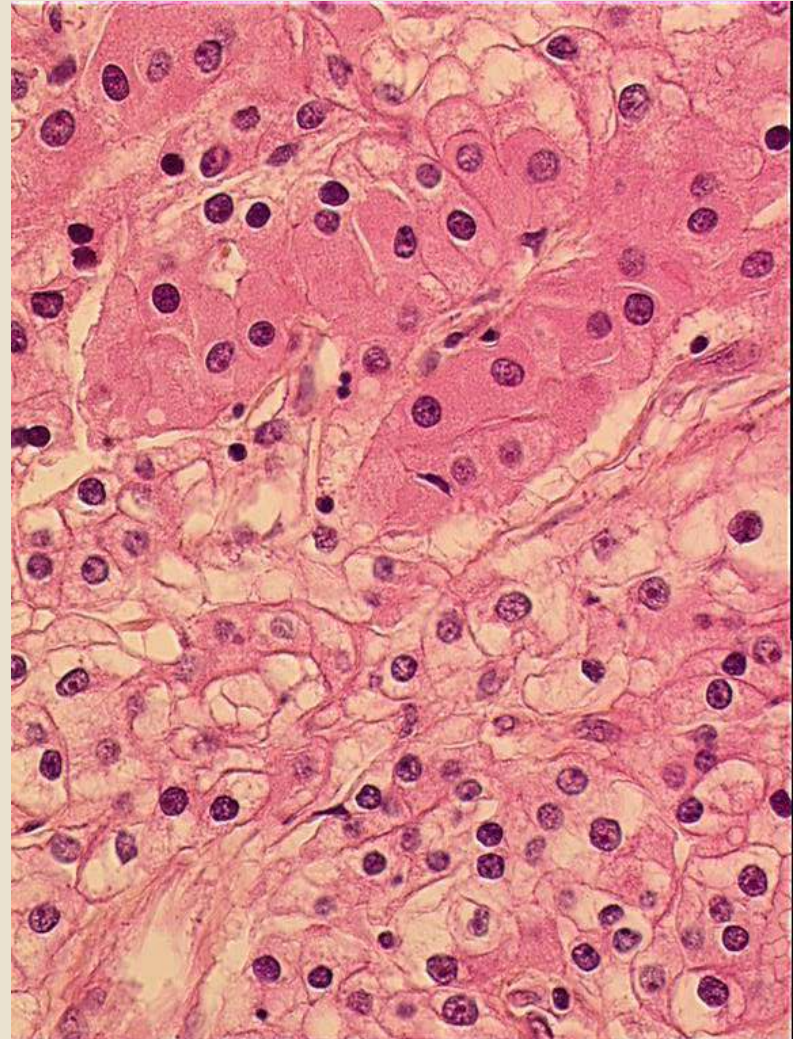
Sporadic >40 y.o.

Clear (slightly eosinophilic) cells

Alveolar trabecular massive cystic architecture

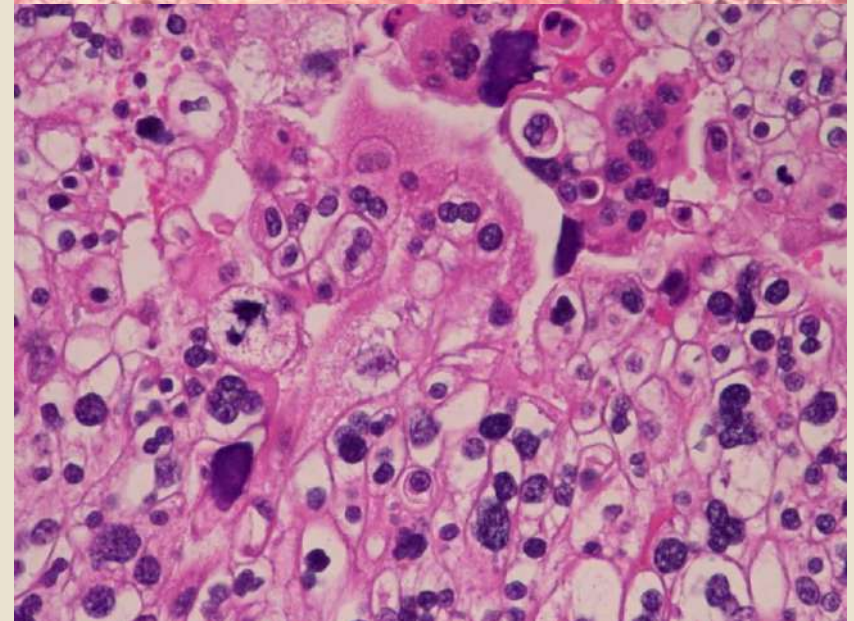
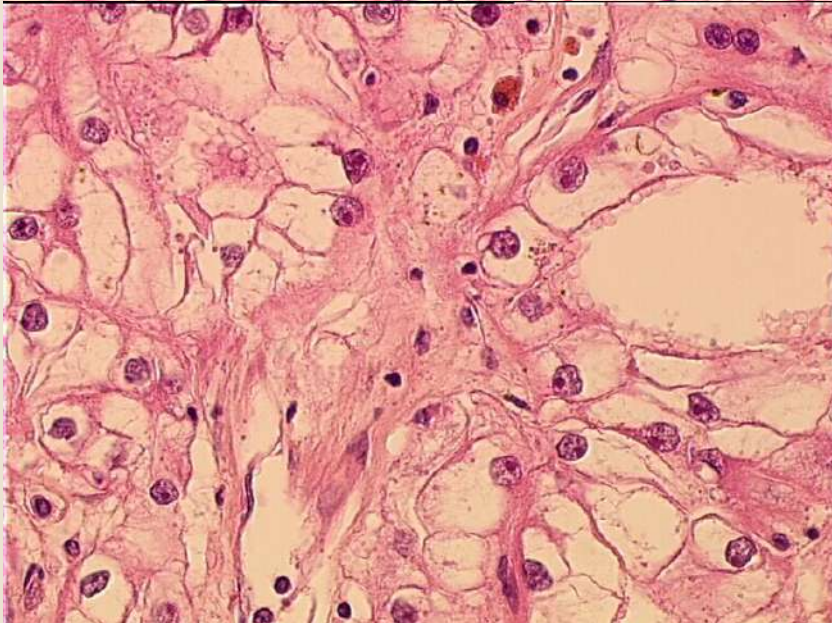
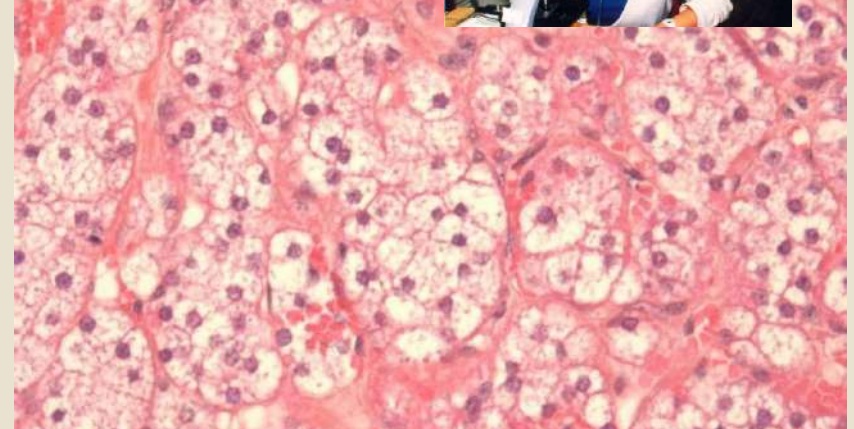
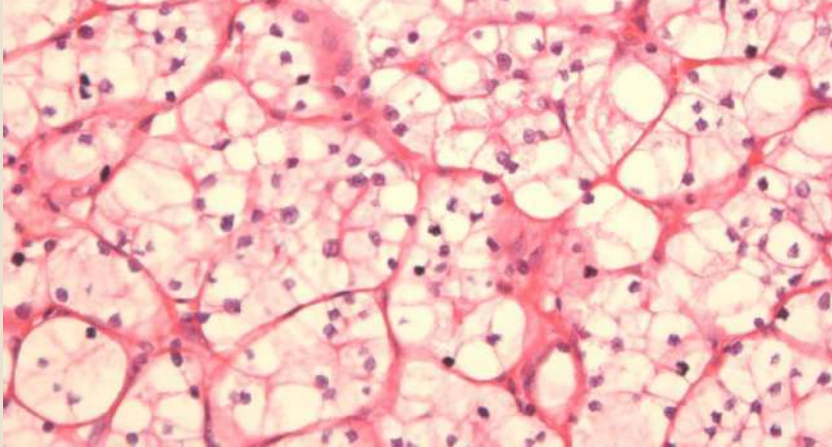
Numerous vessels ++

RCC+ CD10+ VIM + CaIX+
CK7- Racemase +/- CD117-



Grade Fuhrman/ISUP

80% of I



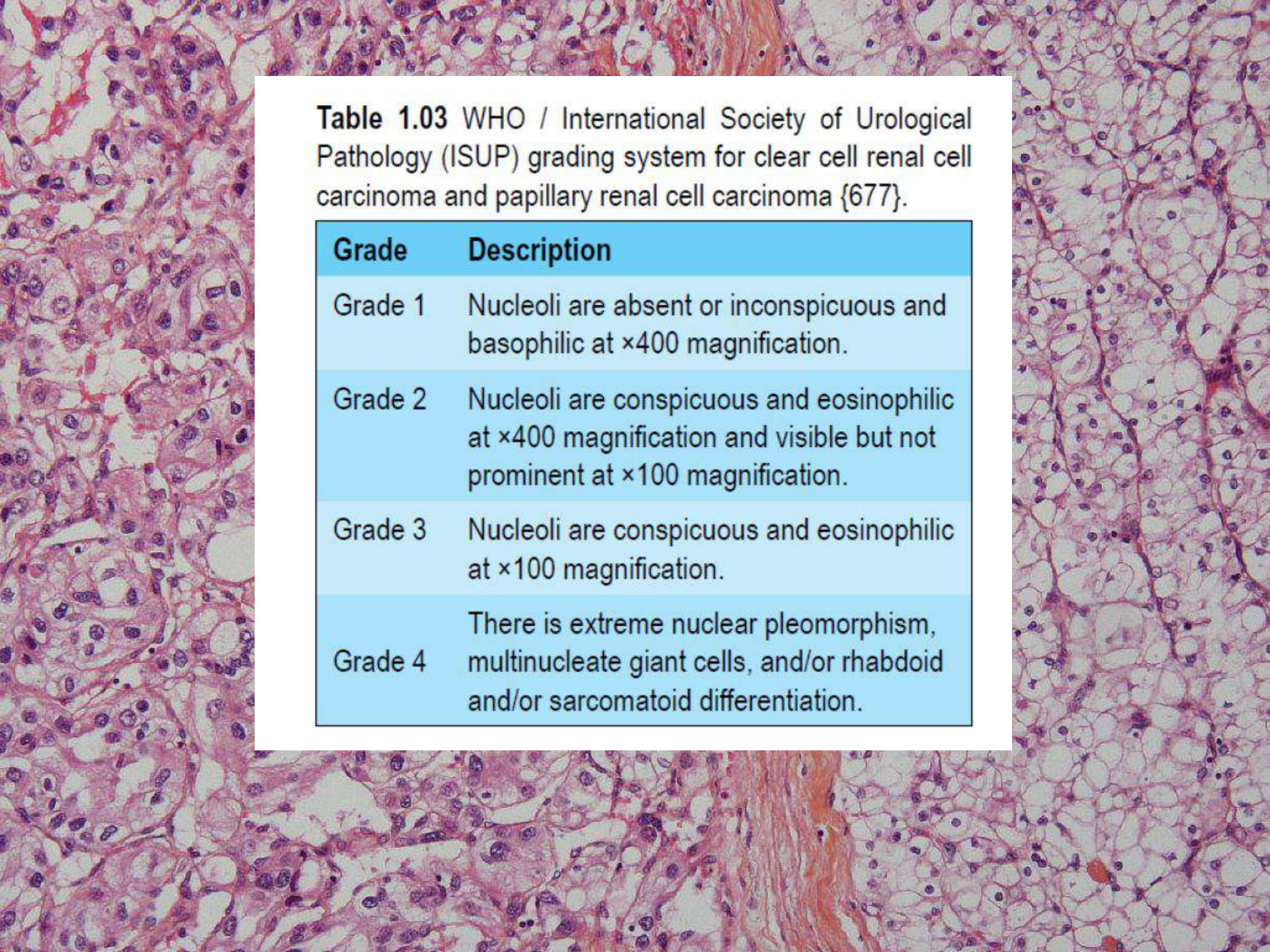


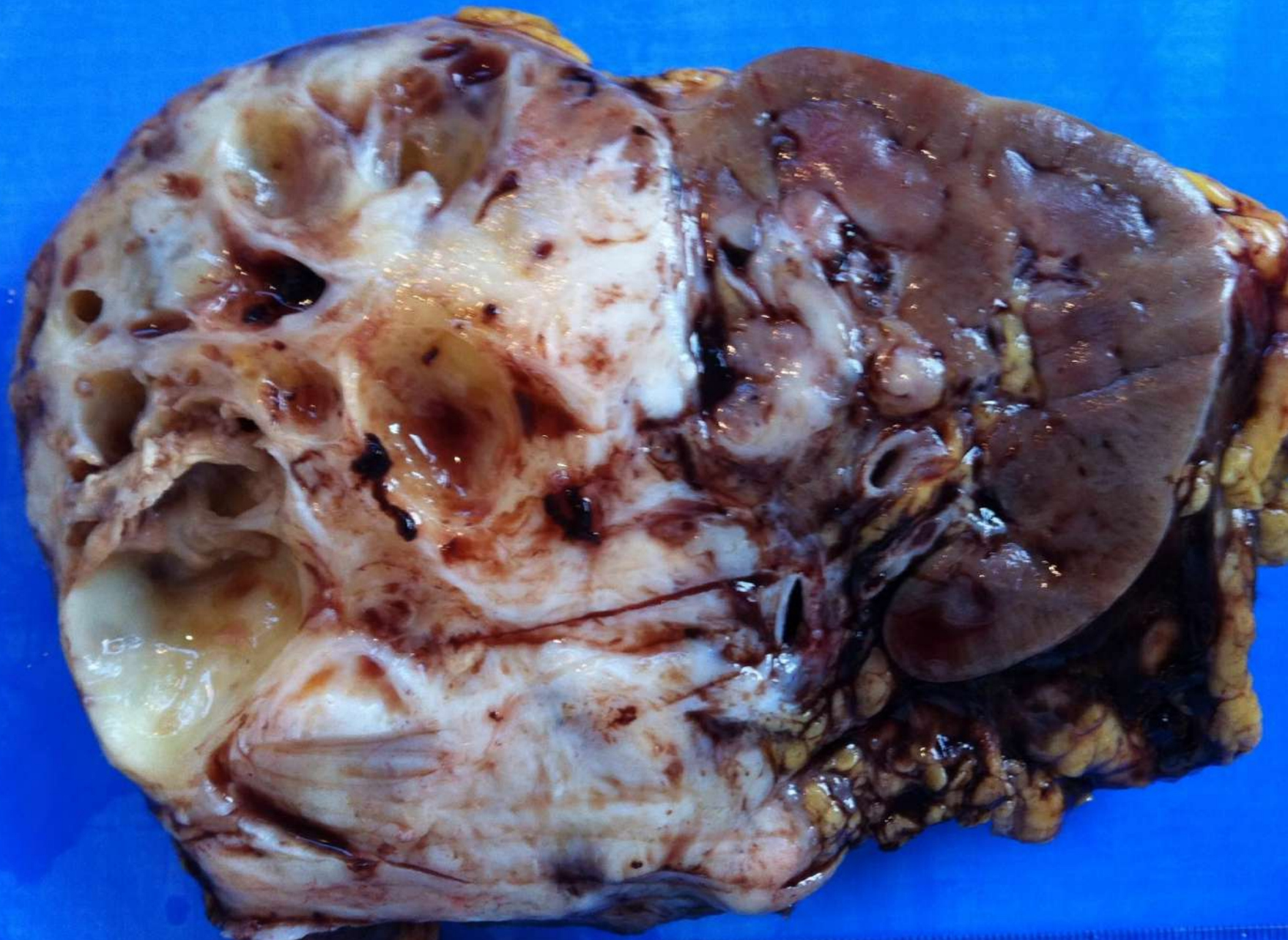Table 1.03 WHO / International Society of Urological Pathology (ISUP) grading system for clear cell renal cell carcinoma and papillary renal cell carcinoma {677}.

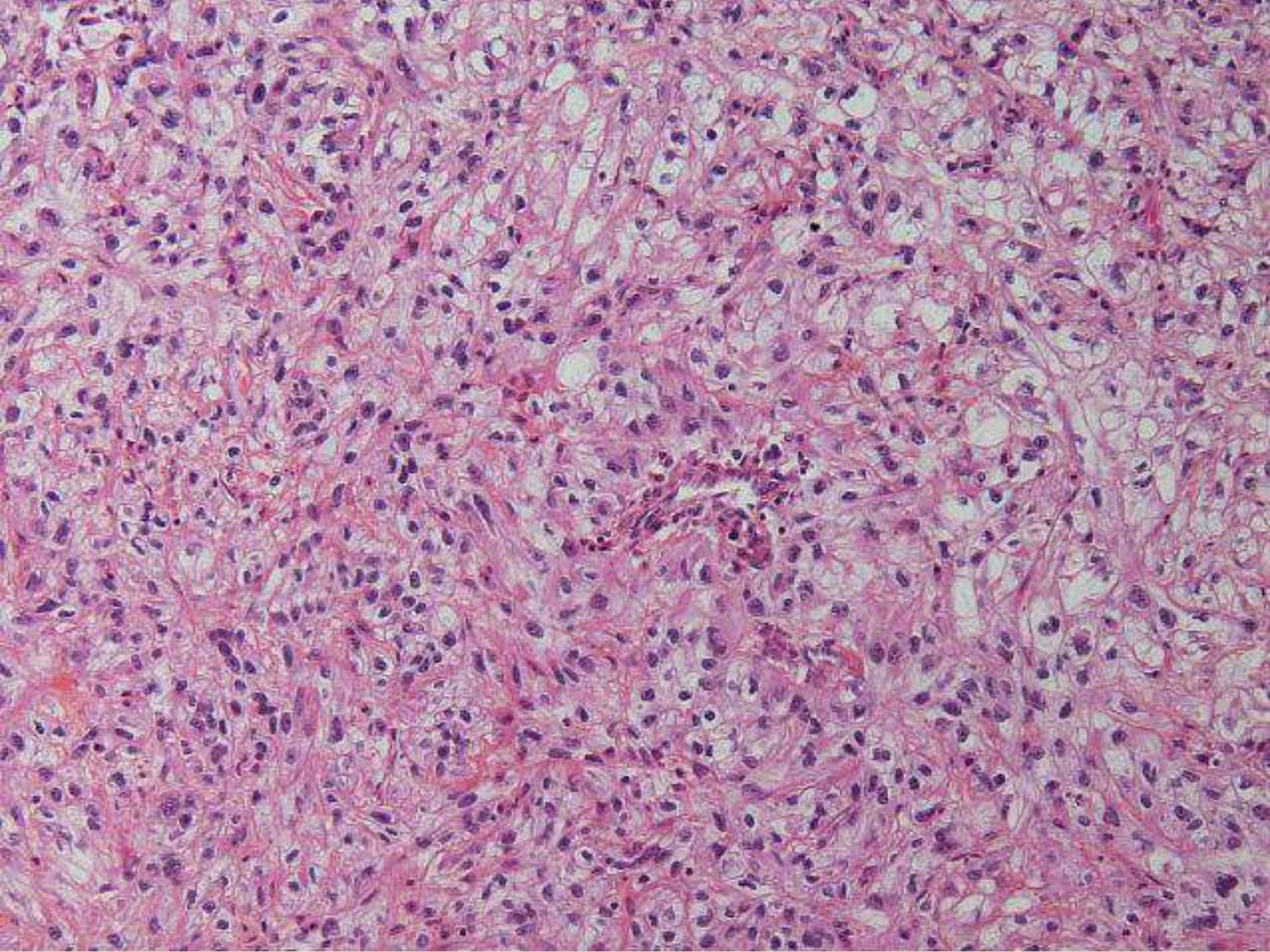
Grade	Description
Grade 1	Nucleoli are absent or inconspicuous and basophilic at $\times 400$ magnification.
Grade 2	Nucleoli are conspicuous and eosinophilic at $\times 400$ magnification and visible but not prominent at $\times 100$ magnification.
Grade 3	Nucleoli are conspicuous and eosinophilic at $\times 100$ magnification.
Grade 4	There is extreme nuclear pleomorphism, multinucleate giant cells, and/or rhabdoid and/or sarcomatoid differentiation.

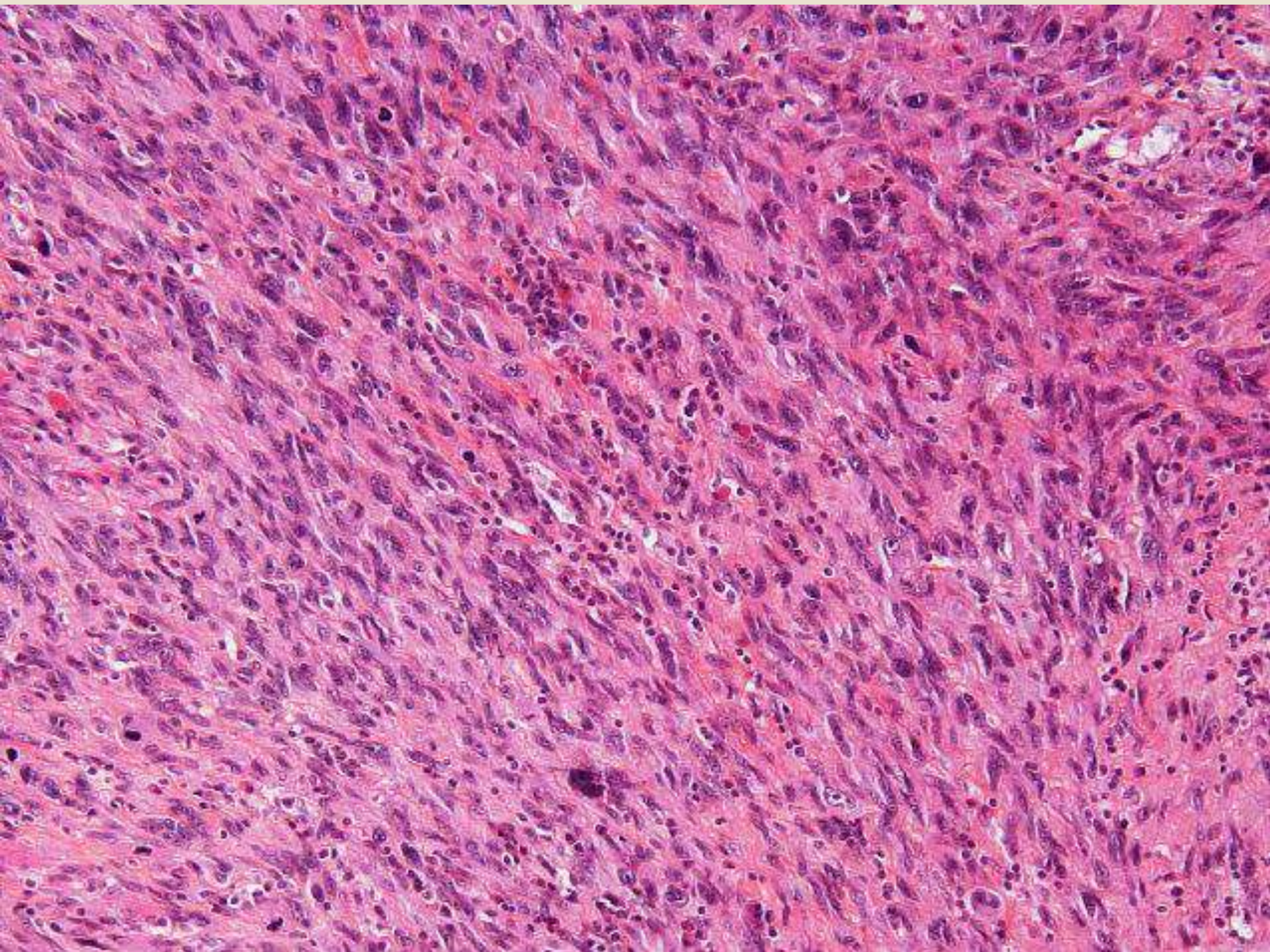
Prognostic factors

Sarcomatoid differentiation

- 1-8%, mainly CCRCC
- 15 à 20 % 5y OS
- Biphasic
 - Heterologous : chondrosarcoma, osteosarcoma, rhabdomyosarcoma, fibrosarcoma...
- Loss of chromosomes 13q or 4q







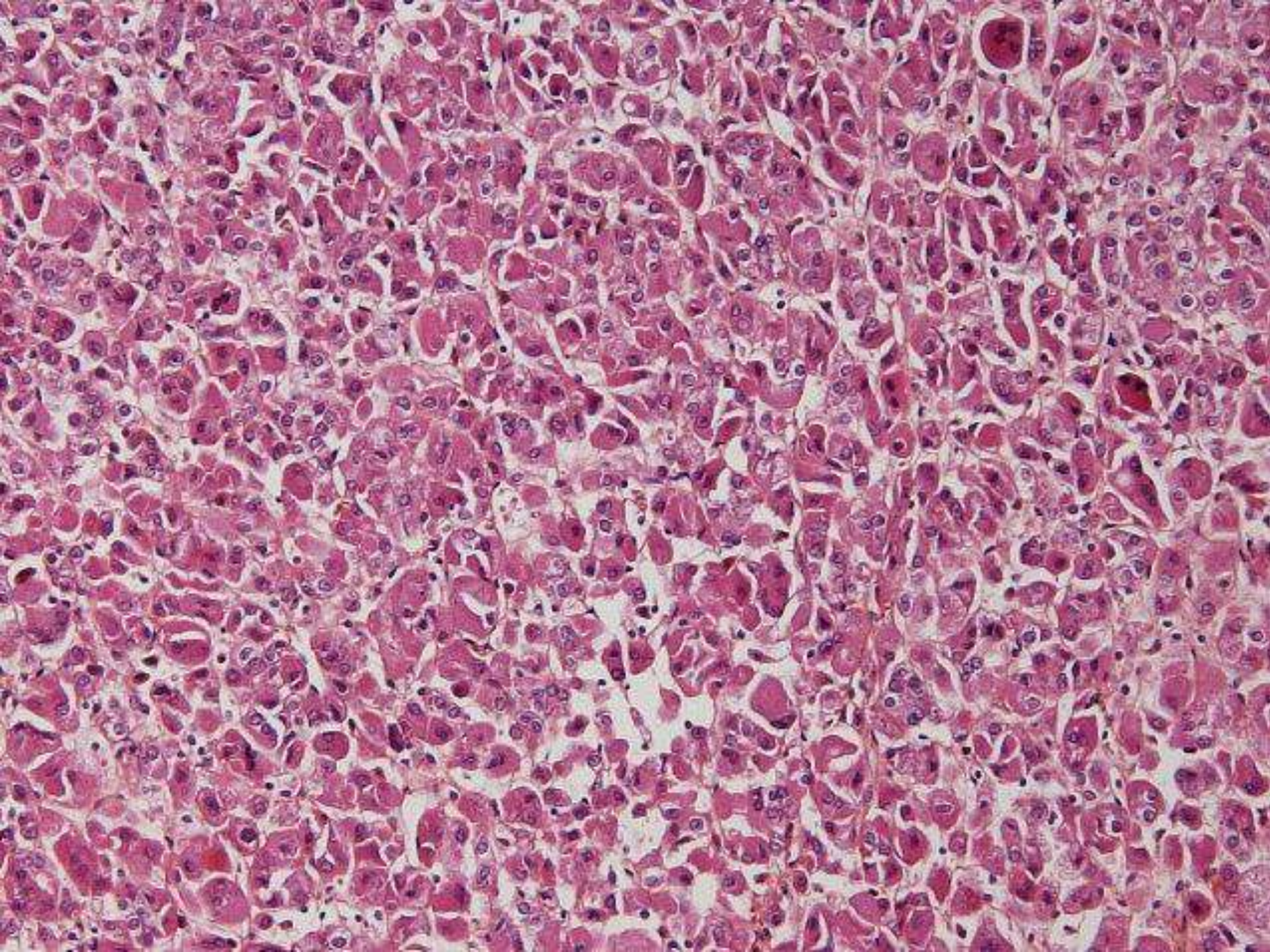
Sarcomatoid differentiation

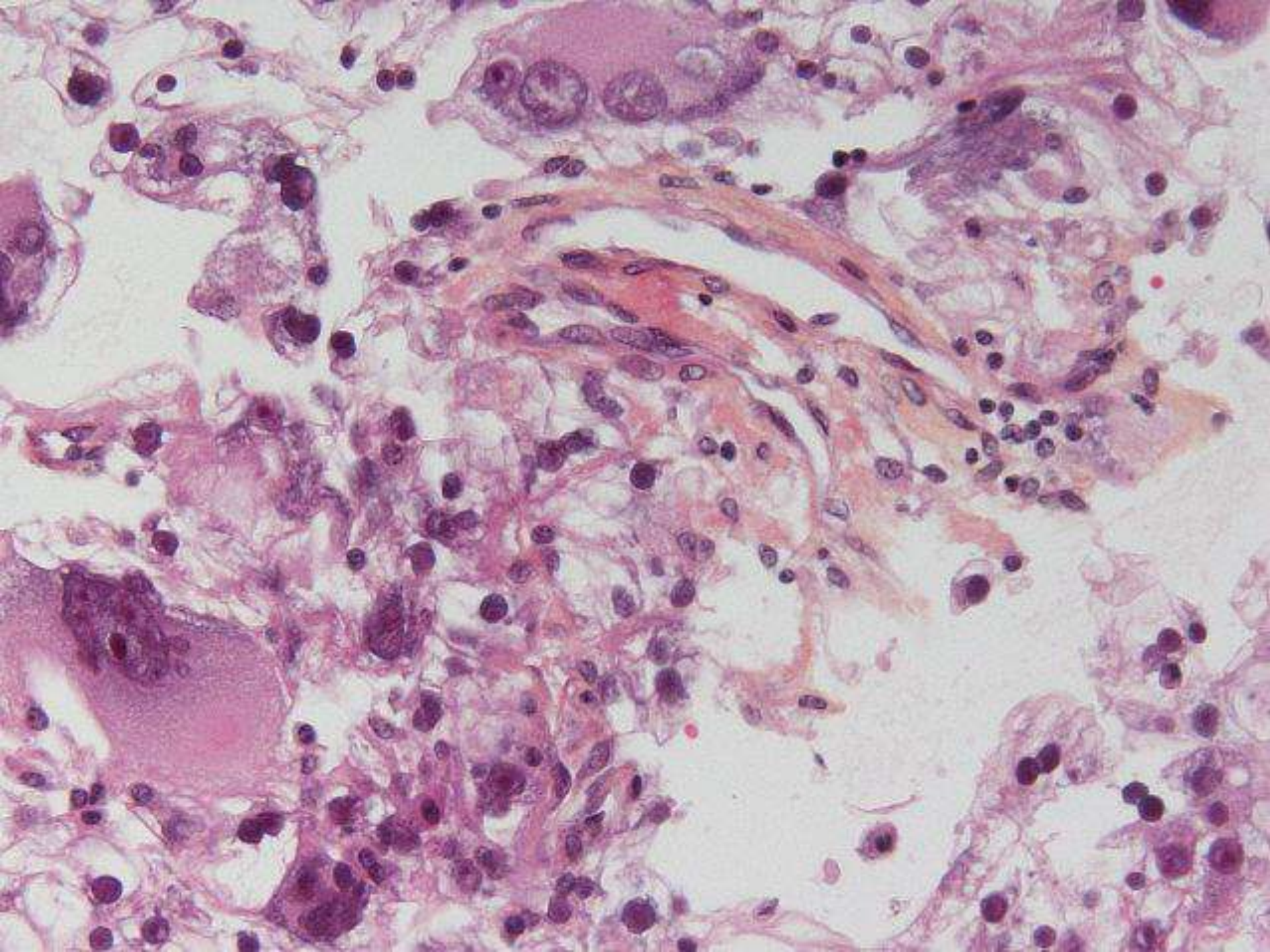
- From 1 to 100% of tumor cells (no need to specify but recommended ICCR)
- if 100% sarcomatoid
 - RCC undifferentiated with 100 % sarcomatoid component
- Always Grade IV

Prognostic factors

Rhabdoid differentiation

- Associated with poor prognosis
- Most often CCRCC



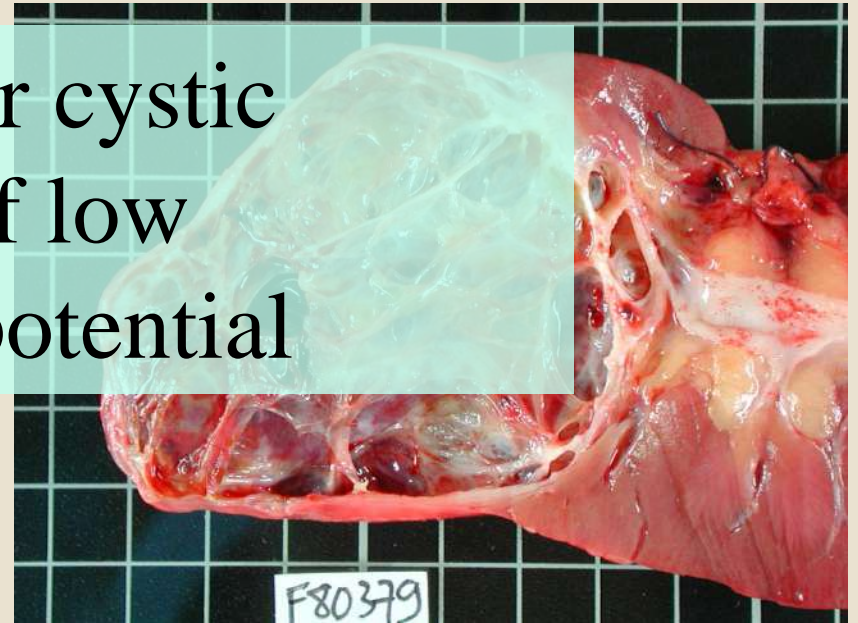
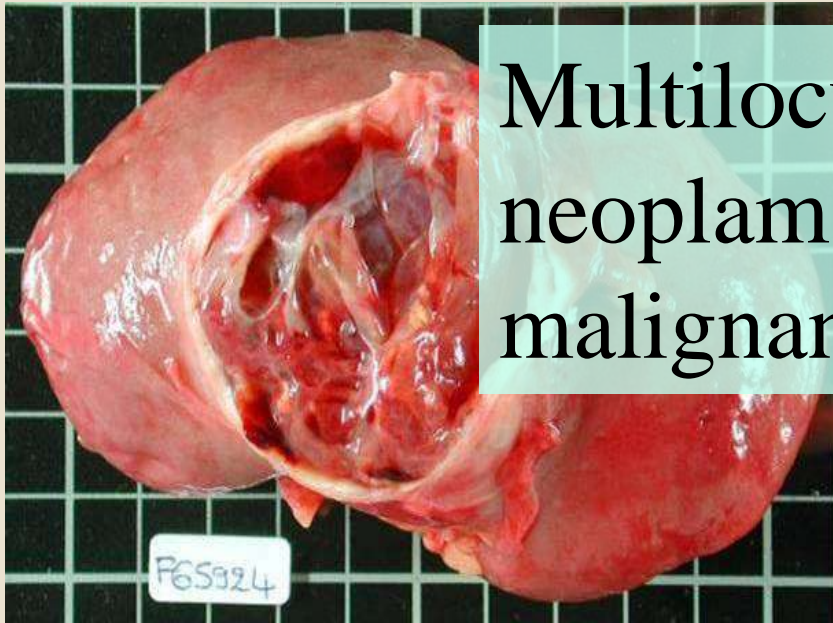


Prognostic factors

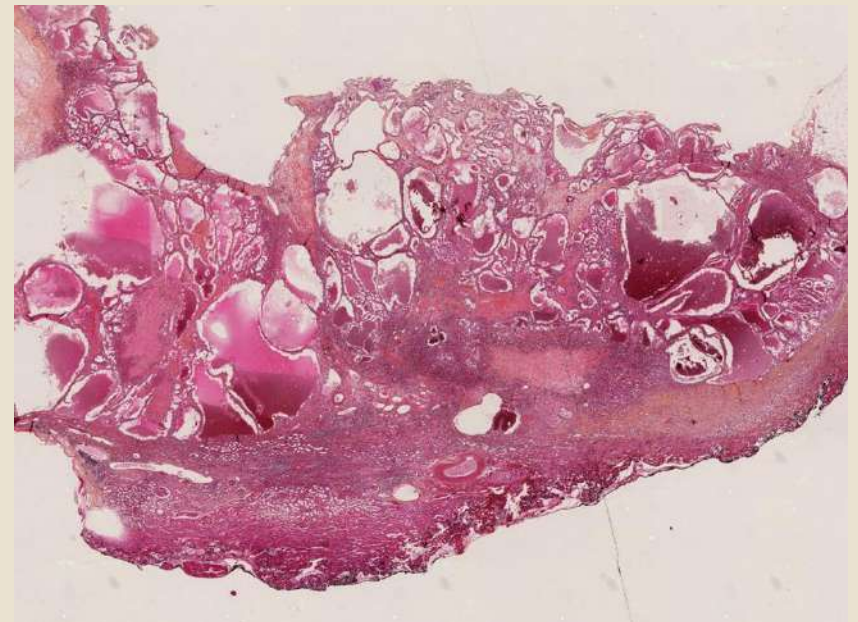
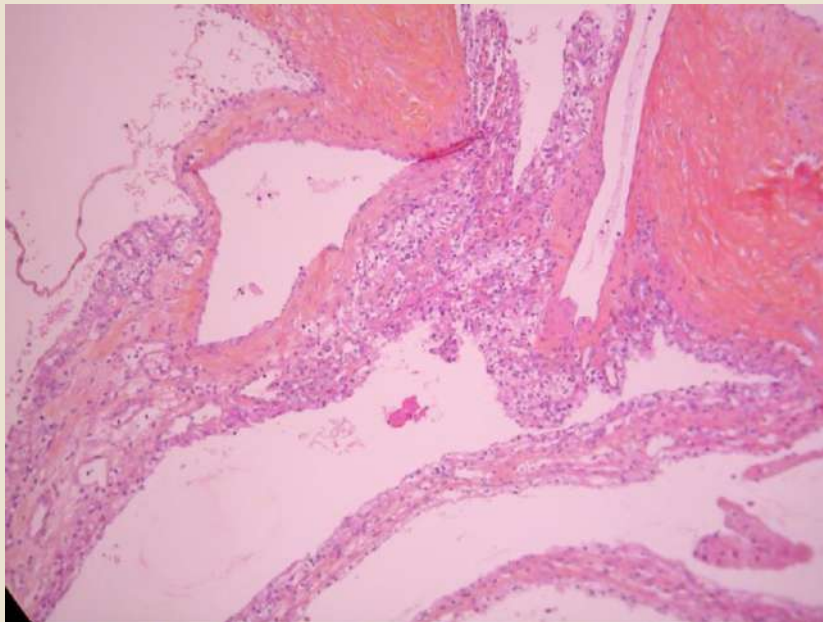
Necrosis

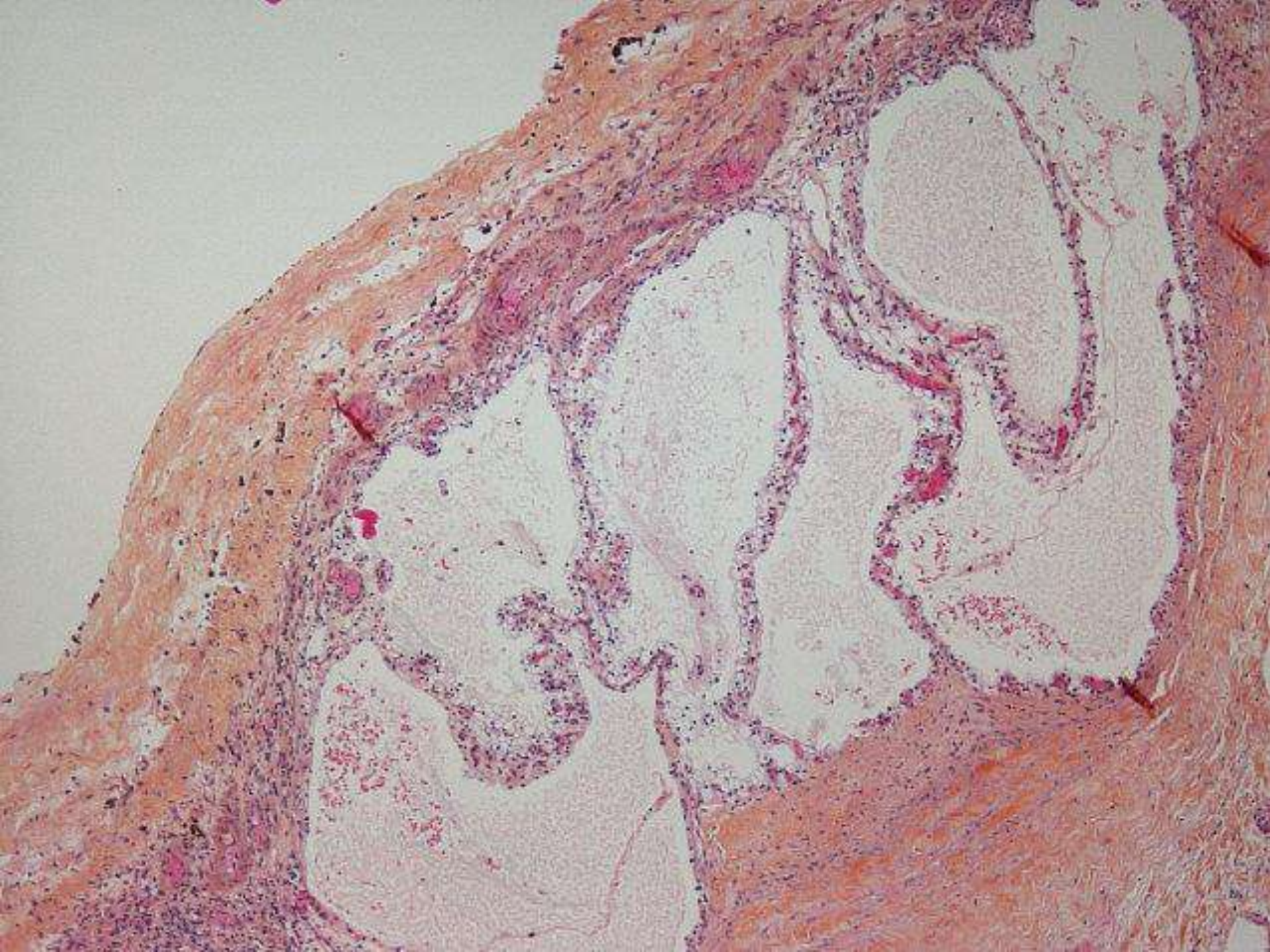
- Poor prognosis
- %
- focal/extensive

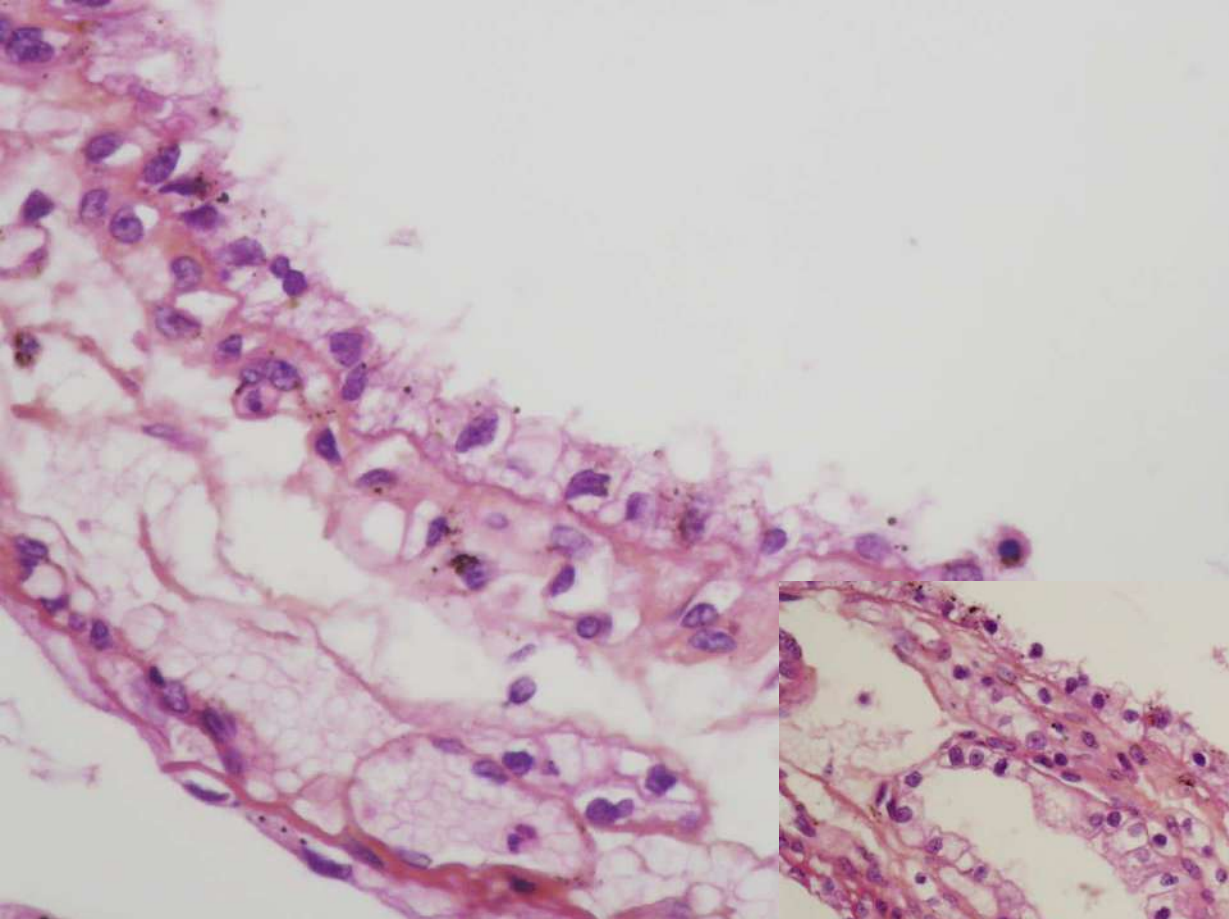
Multilocular cystic neoplasms of low malignant potential



Cystic lesions Bosniak 3 or 4

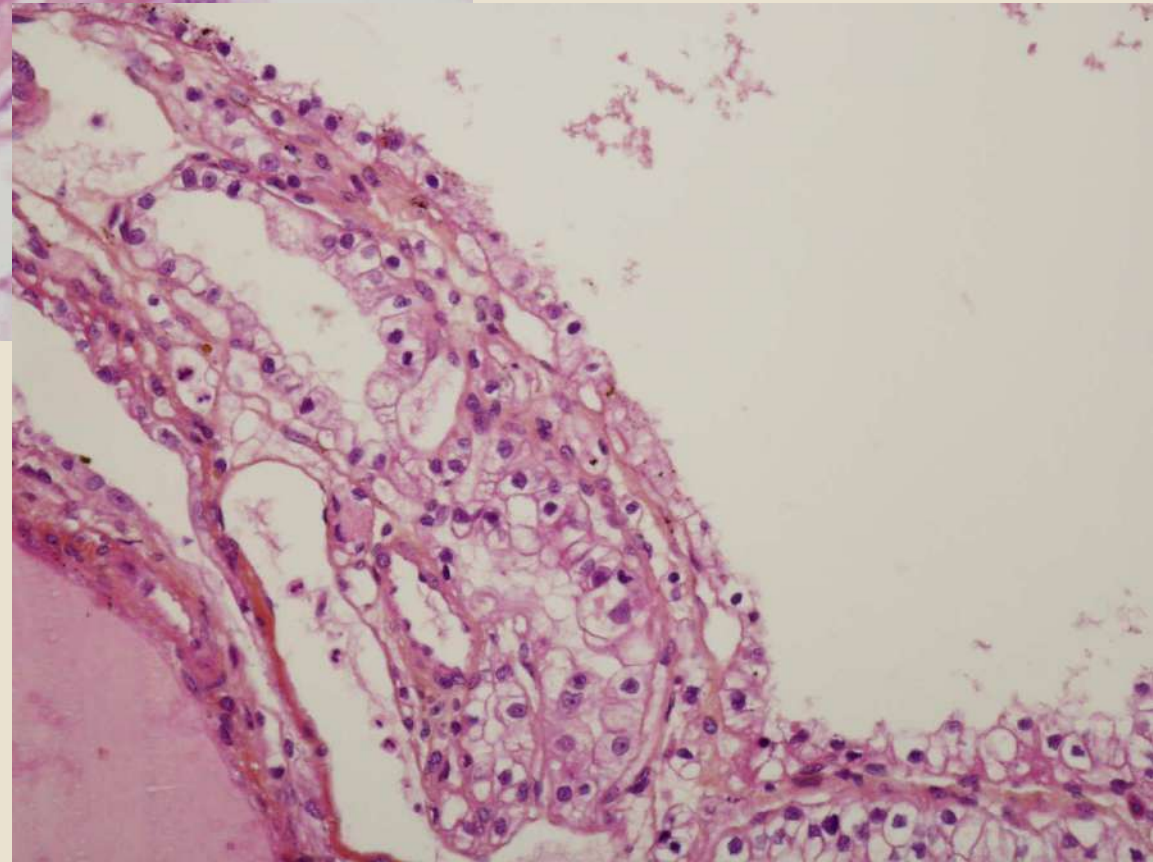






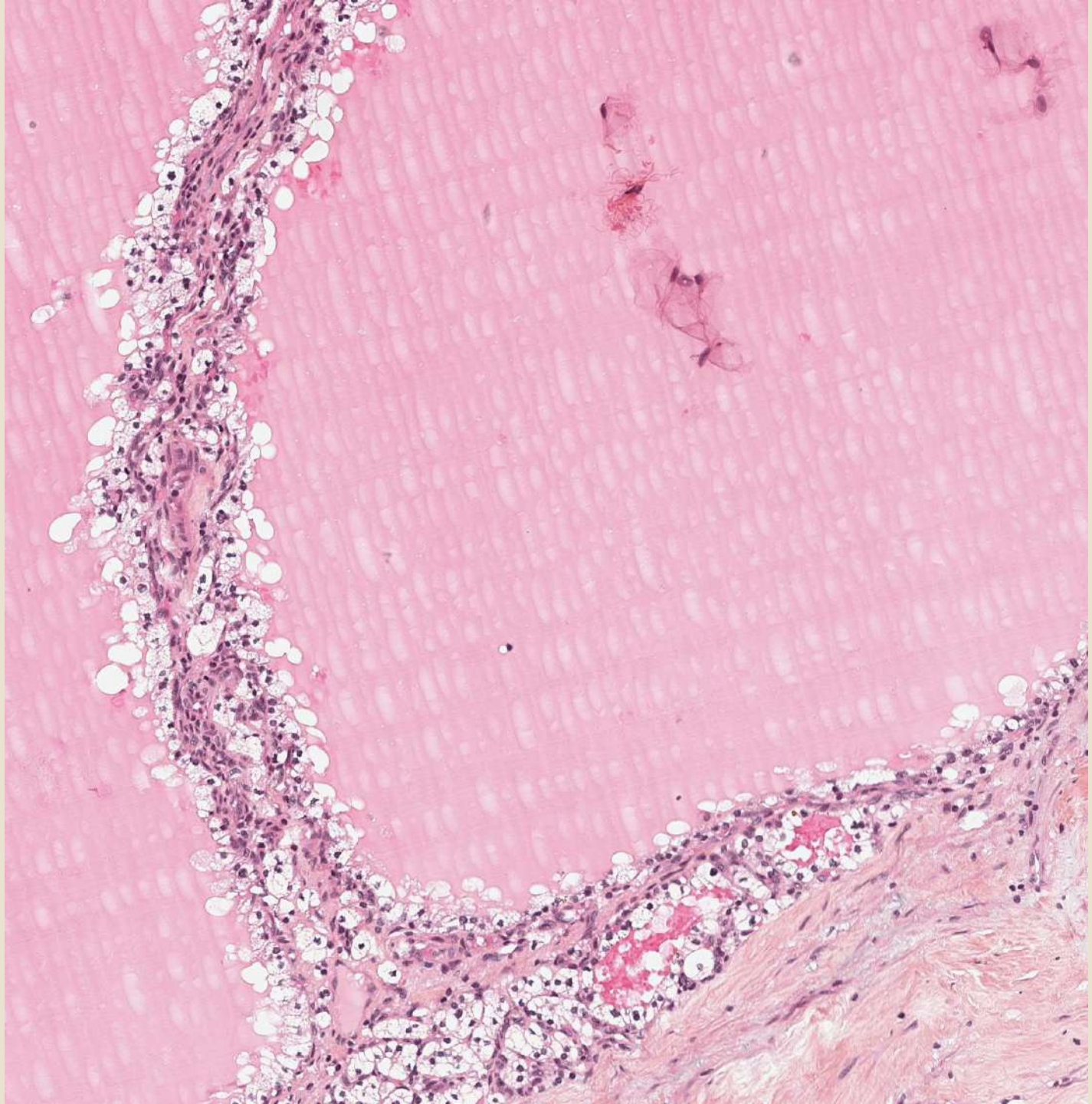
Cysts lined by clear cells

Clusters of clear cells within septas



Variant of CCRCC
Low Fuhrman grade

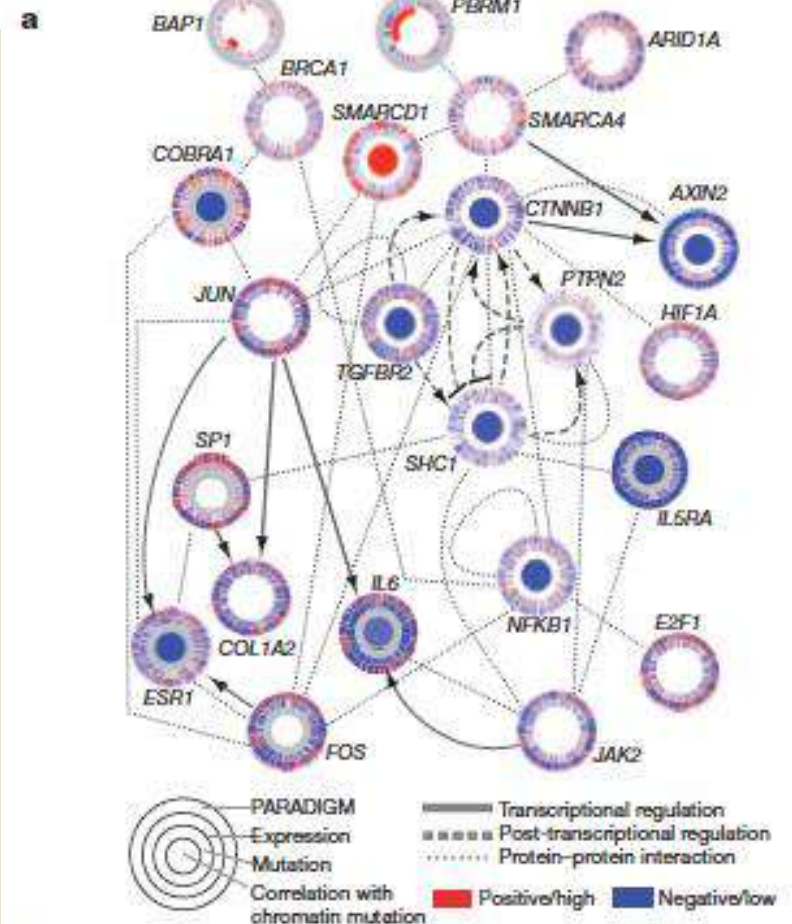
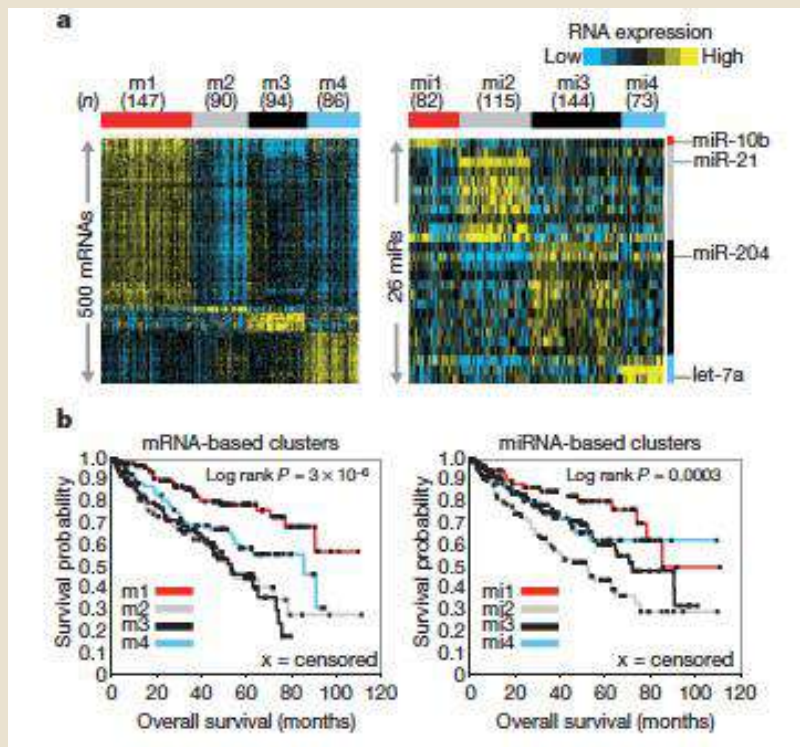
Treatment :
Complect exision



Comprehensive molecular characterization of clear cell renal cell carcinoma

The Cancer Genome Atlas Research Network*

Nature 2013 49:43-49



BAP 1 : Peña-Llopis S et col. BAP1 loss defines a new class of renal cell carcinoma. Nat Genet. 2012;44:751–759.

BRCA1 associated protein-1

Cell proliferation and DNA stabilization and repair (BRCA1).

BAP1 mutation in lung and breast cancers, mélanomas, mesothéliomas

PBRM1 : Dalgliesh GL, et col. Systematic sequencing of renal carcinoma reveals inactivation of histone modifying genes Nature. 2010 Jan 21; 463(7279): 360–363.

Polybromo-1

Part of Switch/Sucrose NonFermentable (SWI/SNF)

complex. DNA stabilisation and repair.

In CCRCC

Inactivating mutations of BAP1 : 10-15%

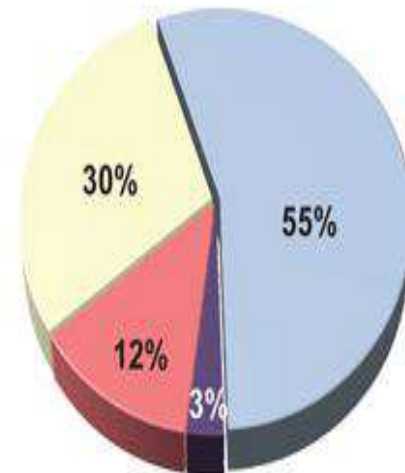
Inactivating mutations of PBRM1 : 50-53%.

***BAP1* and *PBRM1* mutations are largely mutually exclusive in meta-analysis**

Study	<i>n</i>	<i>PBRM1</i>	<i>BAP1</i>	<i>BAP1/ PBRM1</i>
Peña-Llopis <i>et al.</i>	176	89	21	3
Guo <i>et al.</i>	98	21	8	1
Hakimi <i>et al.</i>	185	53	10	1
TCGA	293	101	22	5
Total	576	175	40	6

b

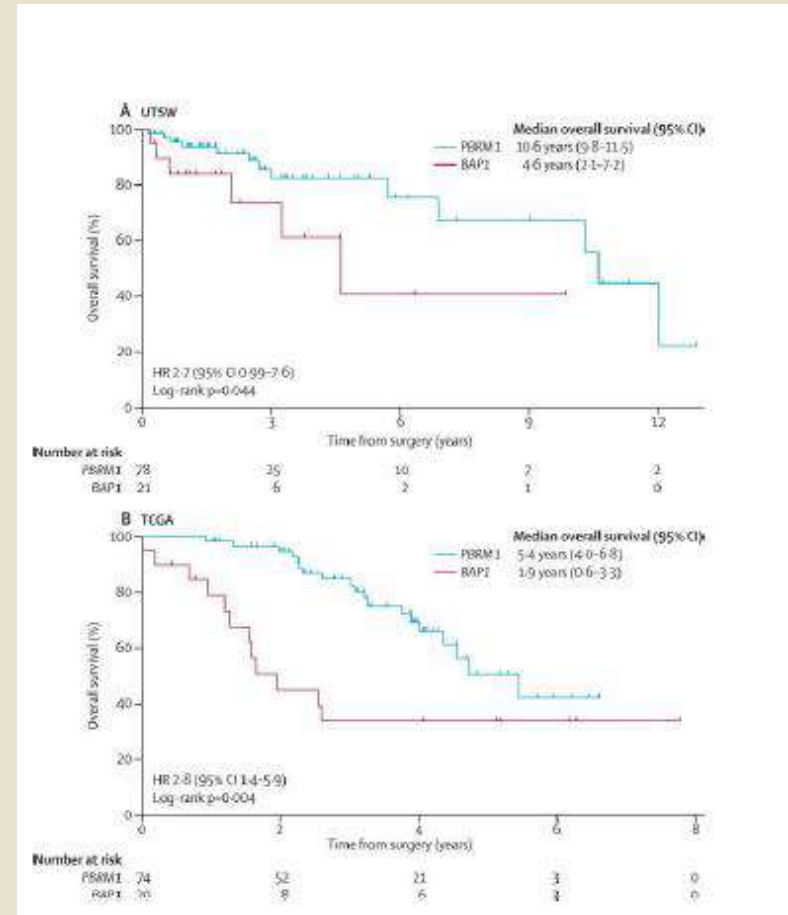
wt BAP1 loss PBRM1 loss BAP1/PBRM1 loss



PBRM1 and BAP1 mutated CCRC have distinct prognosis

Inactivating mutations of BAP1 associated with

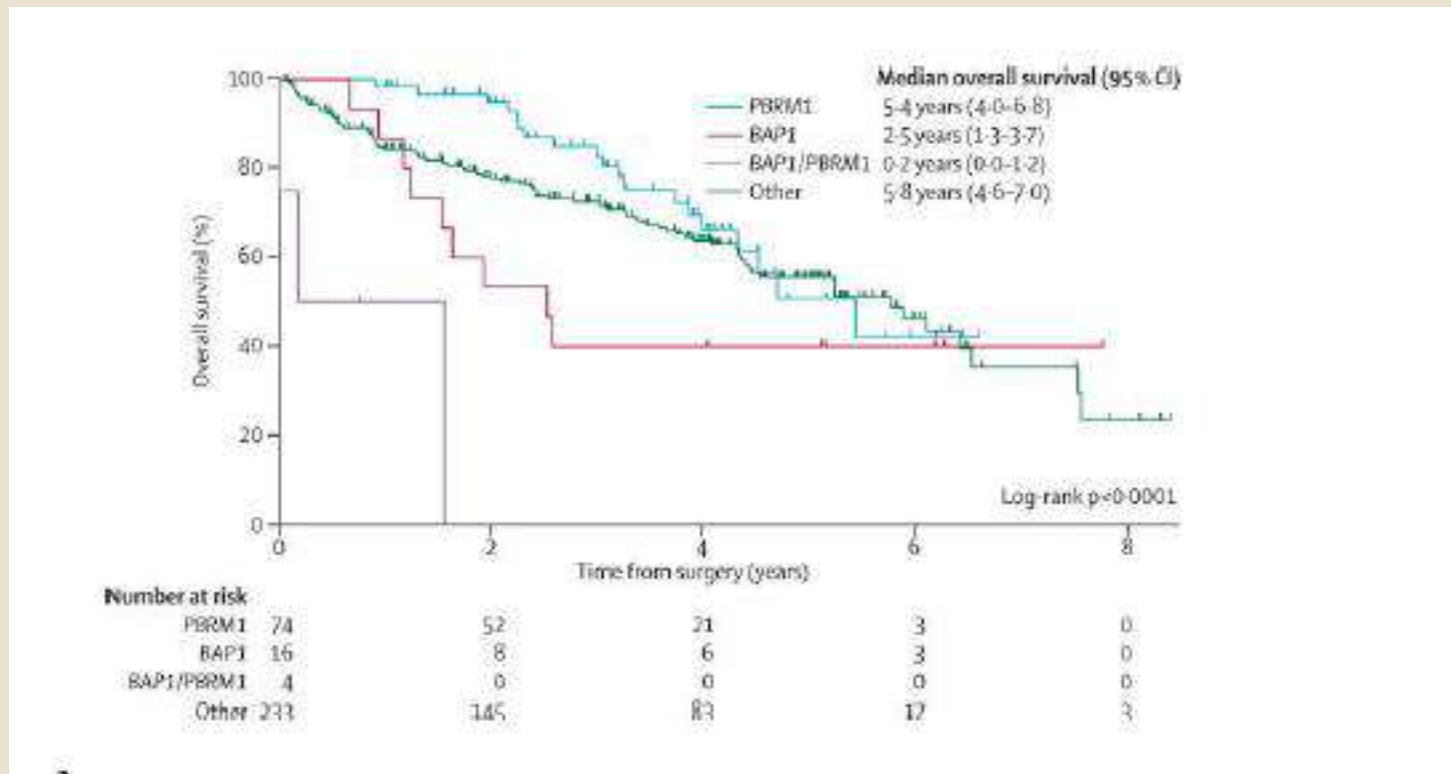
- high risk tumors (HR 7,71 95% CI 2,08-28,6 p=0002)
- Shortened OS (4,6 y (95% CI 2,1-7,2) vs 10,6 y for PBRM1 mutations (95% CI 9.8-11.5).



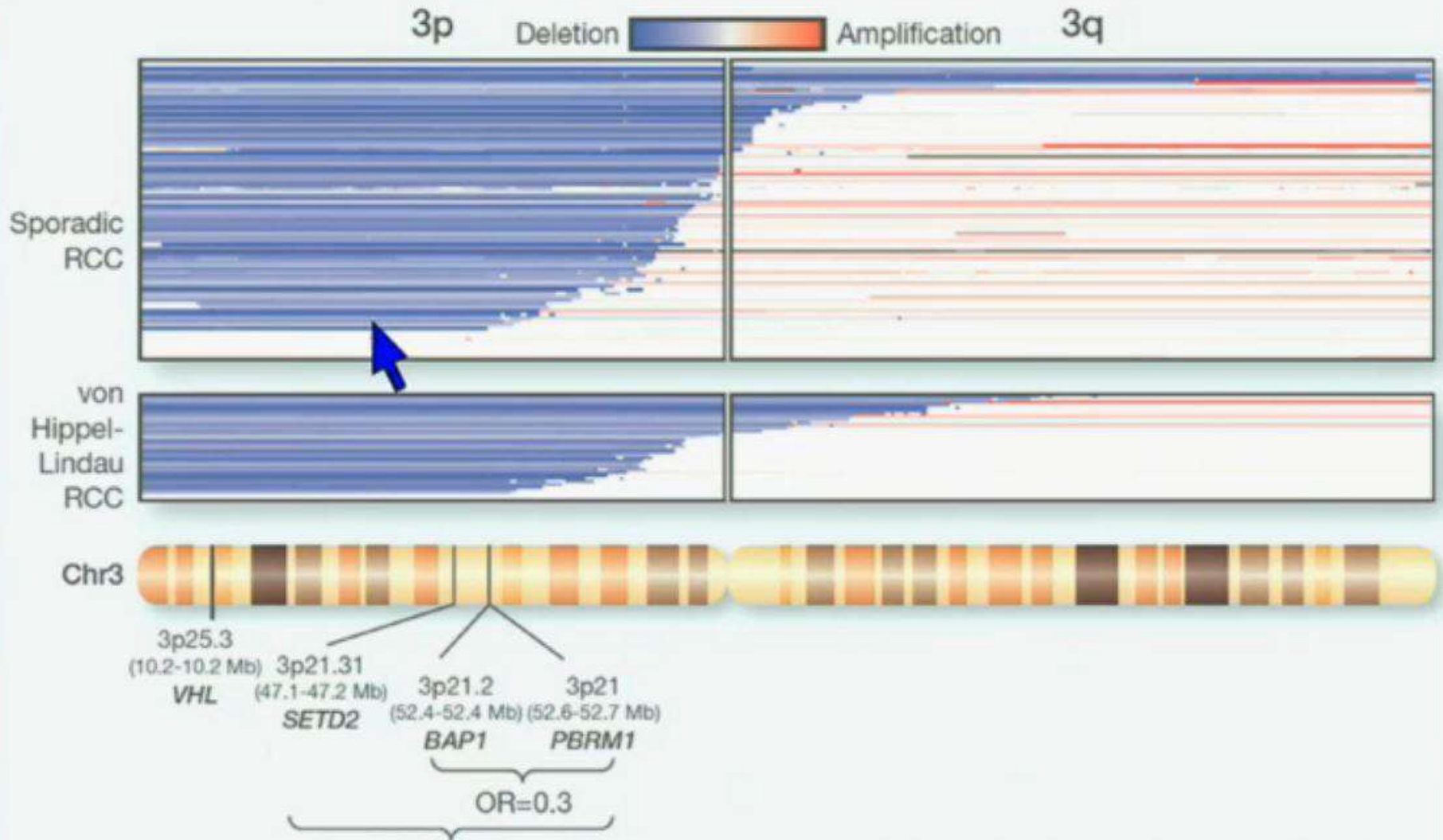
Effects on survival of *BAP1* and *PBRM1* mutations in sporadic clear-cell renal-cell carcinoma: a retrospective analysis with independent validation

P Kapur et coll Lancet Oncology 2013;14:159-67

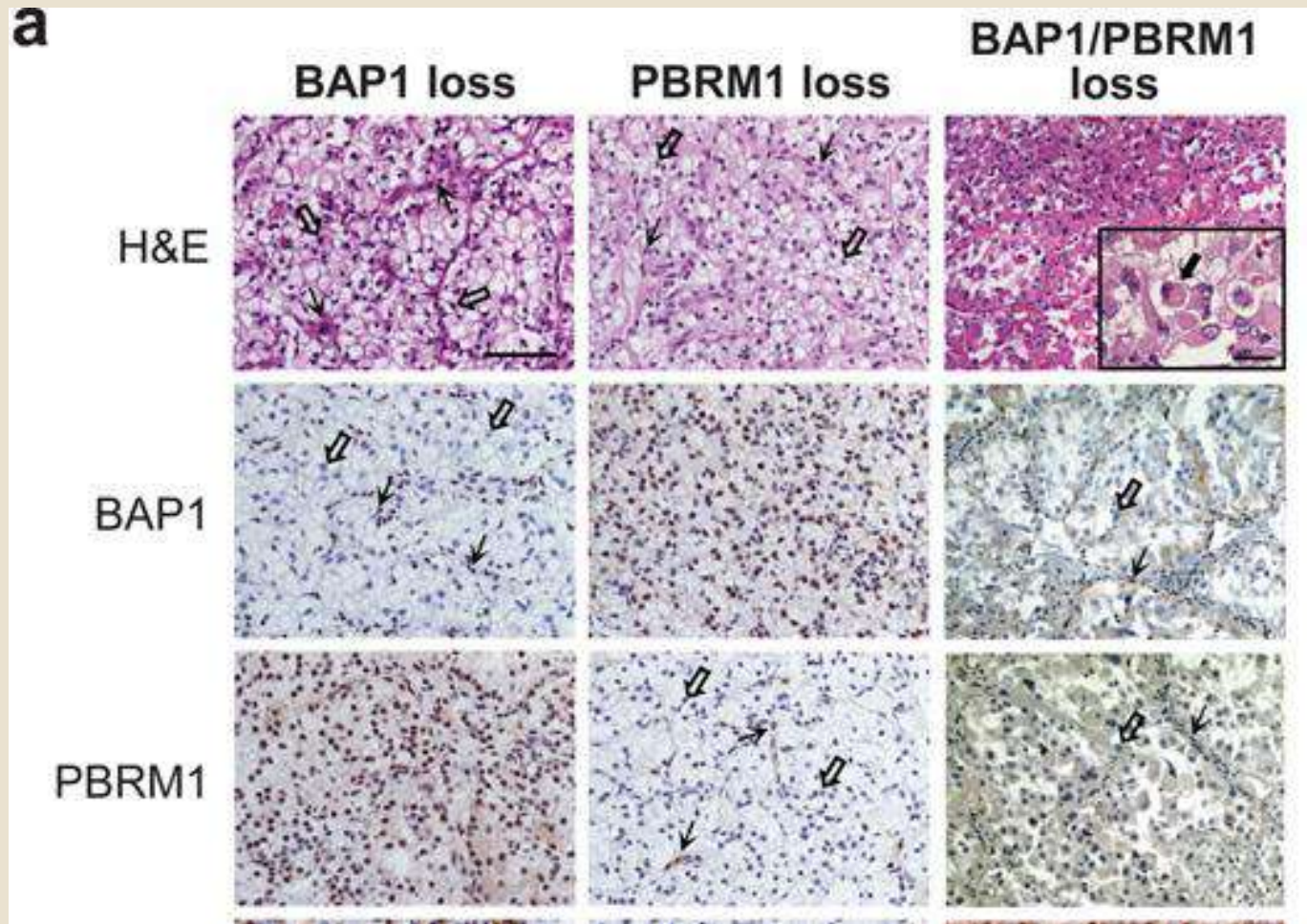
Effects on survival of *BAP1* and *PBRM1* mutations in sporadic clear-cell renal-cell carcinoma: a retrospective analysis with independent validation
 P Kapur et coll Lancet Oncology 2013;14:159-67



BAP1 and *PBRM1* genes are on chromosome 3p and one allele is frequently co-deleted with *VHL* in ccRCC



BAP1 and PBRM1 can be detected by IHC



Joseph RW, Kapur et al. Loss of BAP1 protein expression is an independent marker of poor prognosis in patients with low-risk clear cell renal cell carcinoma. *Cancer*. 2014 Apr 1;120(7):1059-67.

Involved in CCRCC

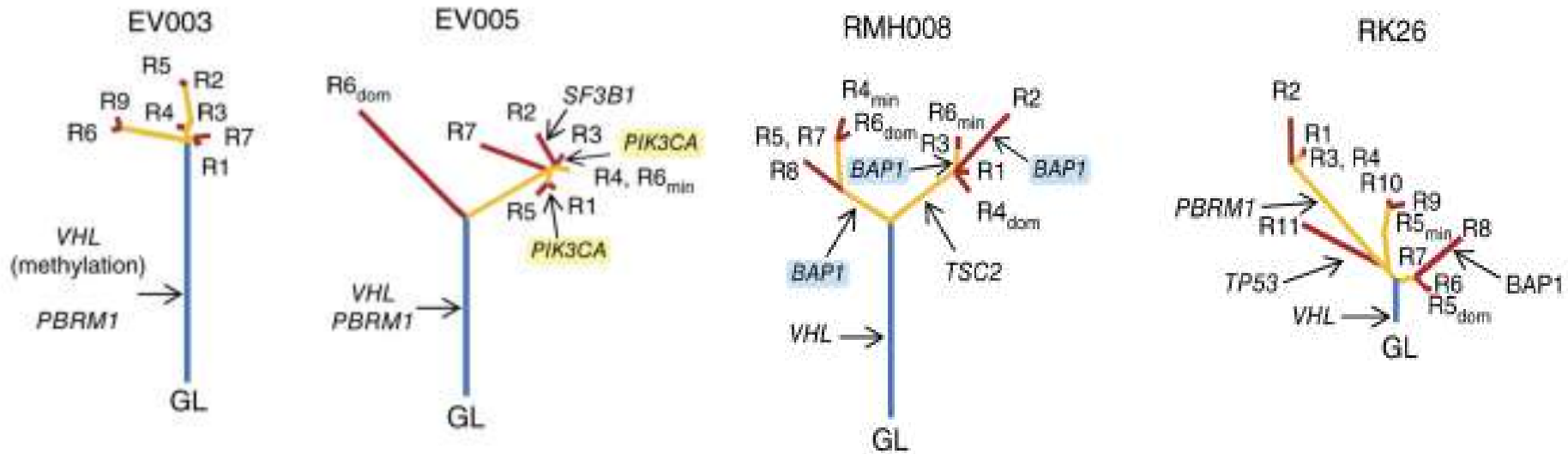
DNA repair and stabilization : 32,4%

SWI/SNF complex : 30,6%

PI3K/AKT/mTOR (15,2%) and p53 : 10,7%

(Cancer Genome Atlas 2013)

Intra tumoral heterogeneity : Genomic alterations are sequential



Gerlinger et coll : nature genet 2014 46:225-233

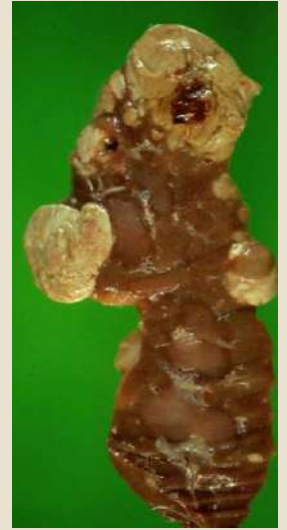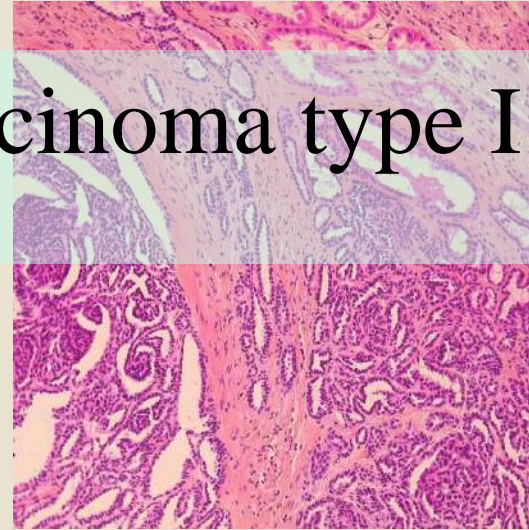
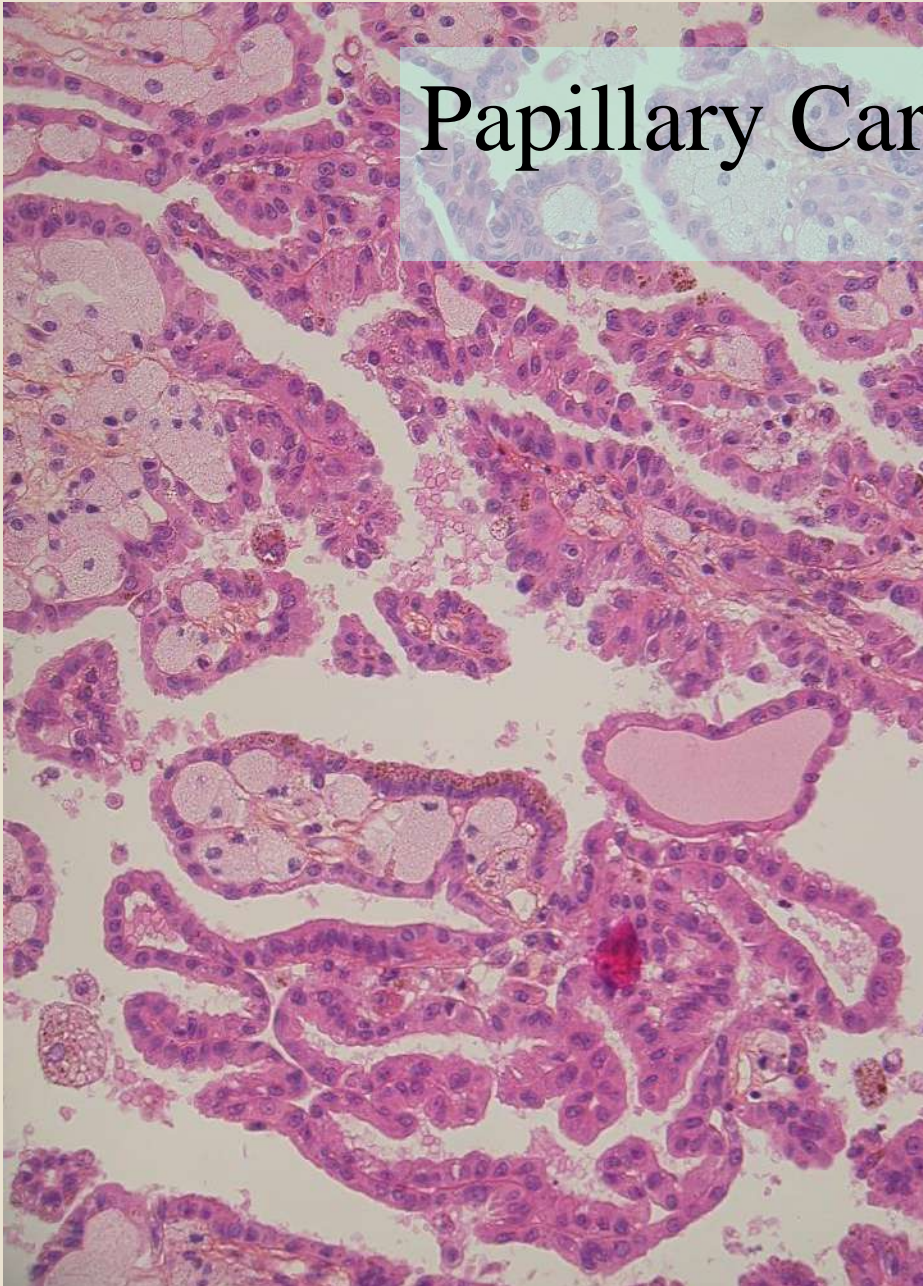
A histological slide showing papillary renal cell carcinoma. The image displays numerous papillary structures, which are finger-like projections of the renal tubules. These structures are lined by a single layer of cuboidal to columnar epithelial cells. The nuclei of these cells are hyperchromatic (darkly stained) and show some degree of pleomorphism. The cytoplasm is eosinophilic (pink). The papillae are separated by a delicate, fibrovascular core. The overall architecture is characteristic of papillary renal cell carcinoma.

Papillary Renal Cell Carcinoma

10% of kidney tumours
Multiples adenomas < 5mm
Carcinoma > 5mm

Type I , non Type I

Papillary Carcinoma type I



Small cuboidal eosinophilic cells

Papillary architecture

Foamy cells

Necrosis, sometimes ++

CK7+ P504+

Usually sporadic and unique

Familial forms multifocal and bitateral

Cmet mutations

Differential diagnosis

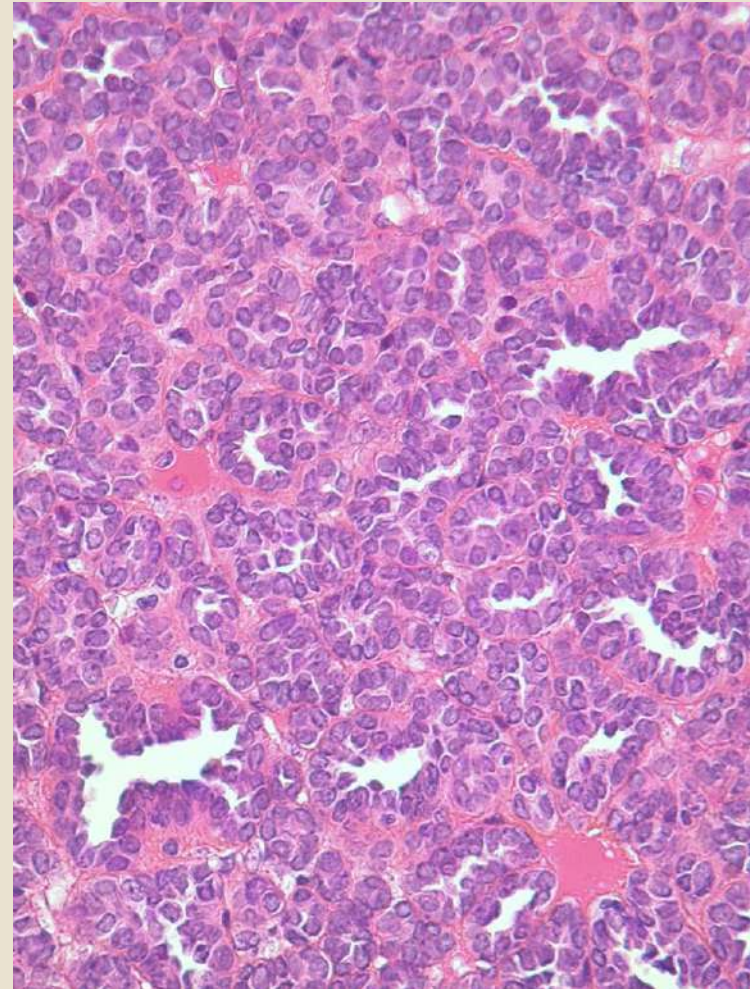
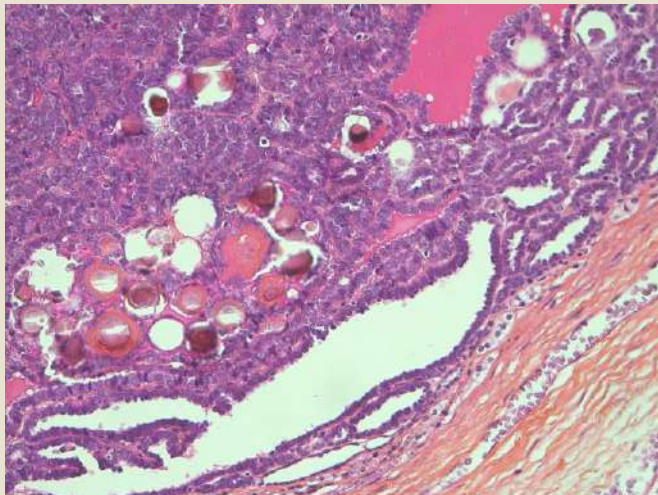
Metanephric adenoma

Rare

Well delimited

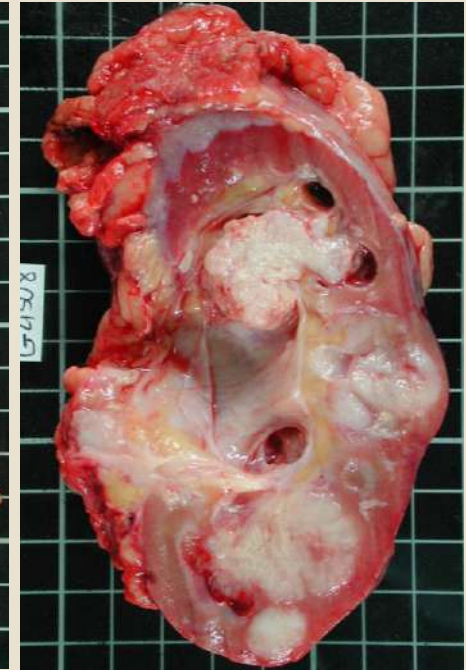
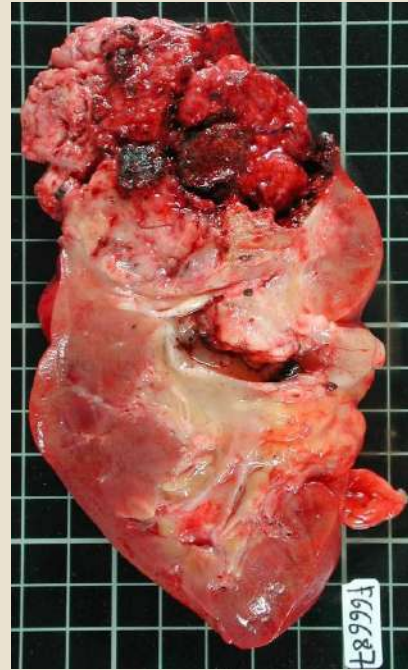
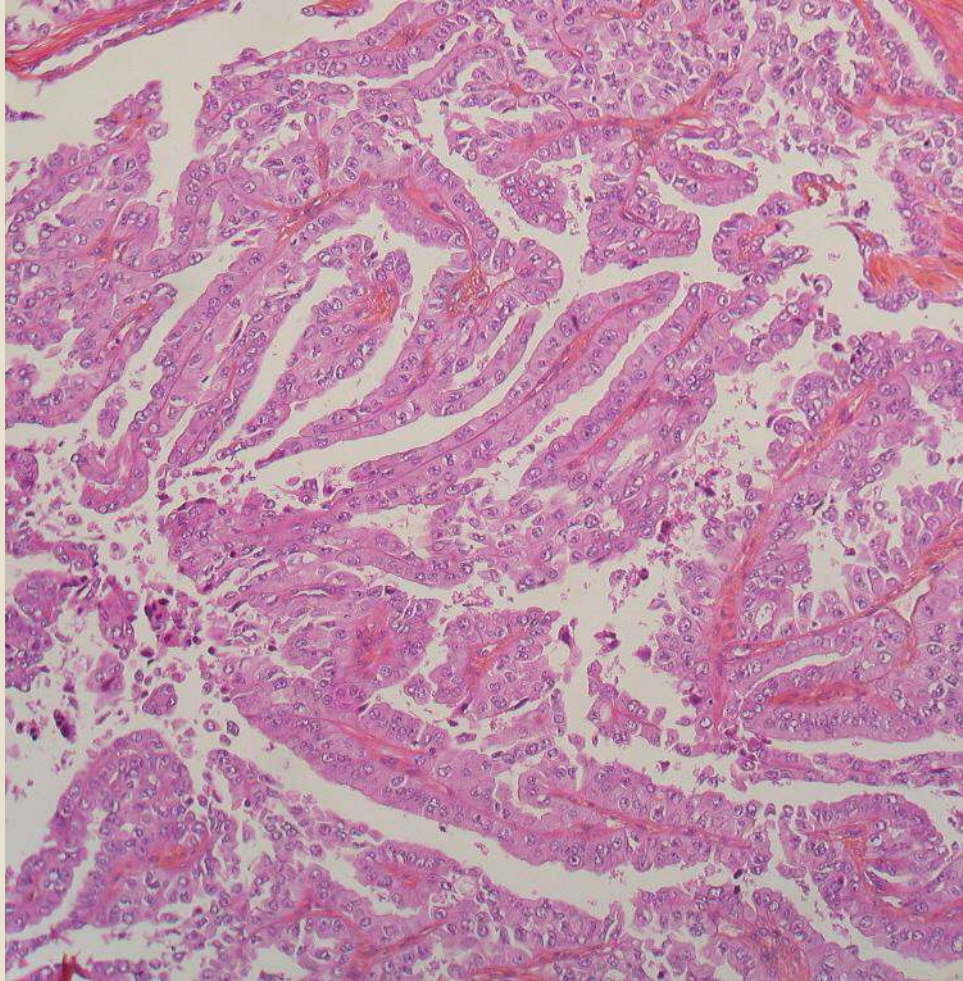
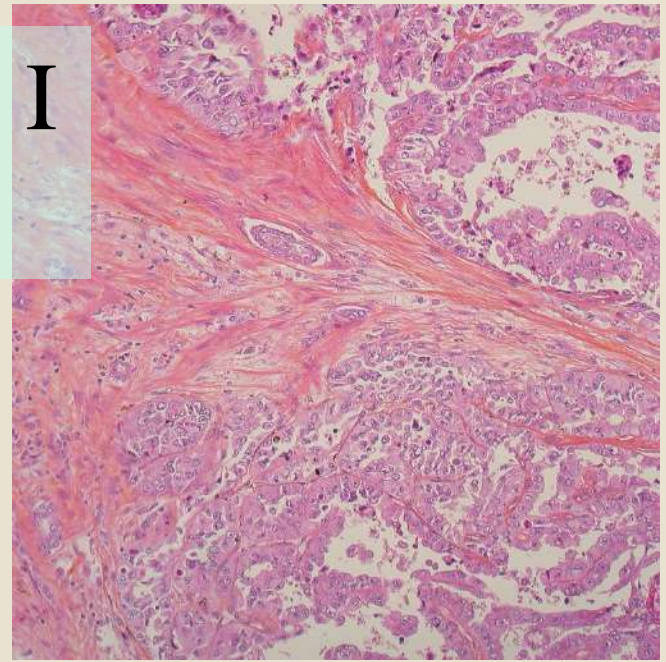
Uniform

CK7- Vim + CD57+ WT1 +



Papillary Carcinoma non type I

An Evolving entity

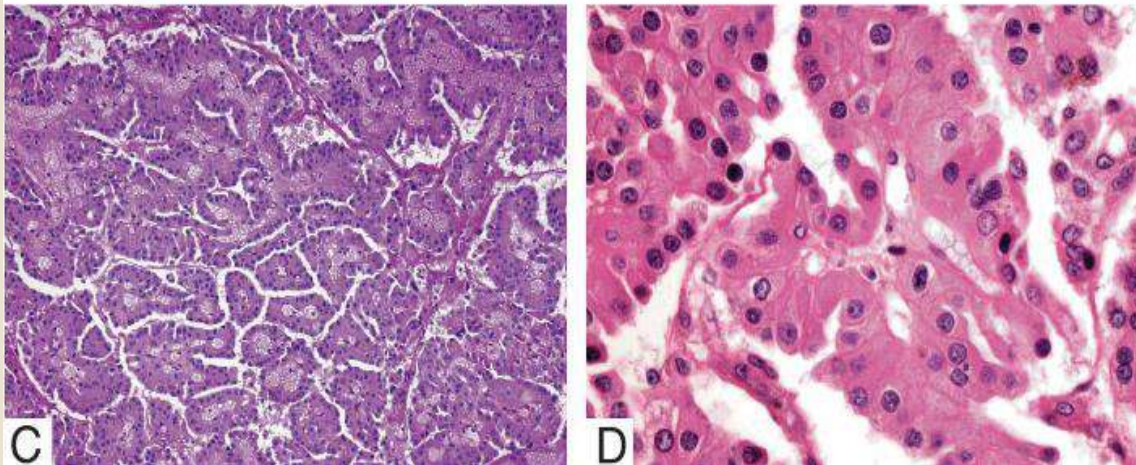
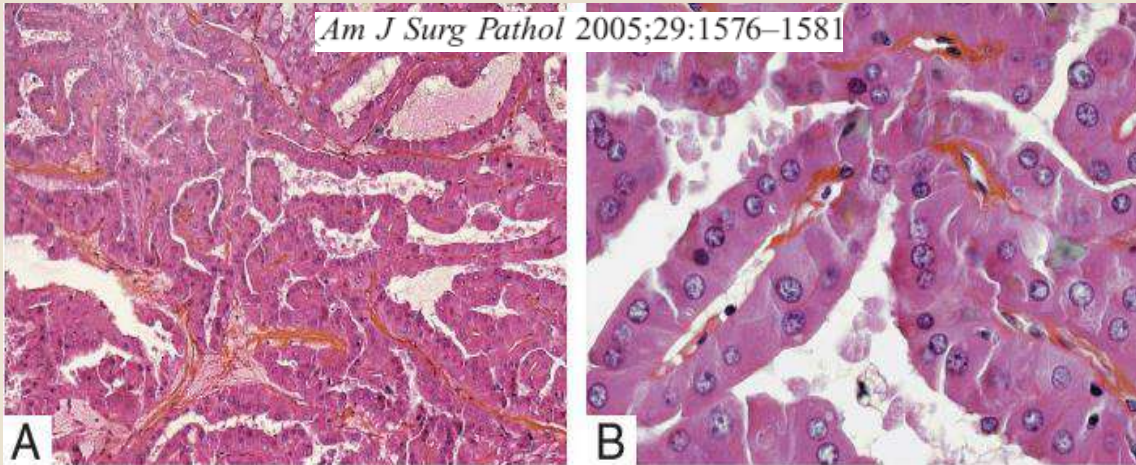


Adult Papillary Renal Tumor With Oncocytic Cells

Clinicopathologic, Immunohistochemical, and Cytogenetic Features of 10 Cases

Marine Lefèvre, MD,* Jérôme Couturier, MD,† Mathilde Sibony, MD, PhD,* Céline Bazille, MD,¶
Karine Boyer, MD,‡ Patrice Callard, MD,* Annick Vieillefond, MD,‡ and Yves Allory, MD*§||

Am J Surg Pathol 2005;29:1576–1581



Papillary renal cell carcinoma with oncocytic cells

Papillary renal cell carcinoma with oncocytic cells and nonoverlapping low grade nuclei: expanding the morphologic spectrum with emphasis on clinicopathologic, immunohistochemical and molecular features

Lakshmi P. Kunju MD^a, Kirk Wojno MD^b, J. Stuart Wolf Jr MD^b,
Liang Cheng MD^c, Rajal B. Shah MD^{a,b,*}

^aDepartment of Pathology, University of Michigan School of Medicine, Ann Arbor, MI 48109, USA

^bDepartment of Urology, University of Michigan School of Medicine, Ann Arbor, MI 48109, USA


^cDepartment of Pathology, Indiana University School of Medicine, Indianapolis, IN 46202, USA

Received 19 March 2007; revised 15 May 2007; accepted 17 May 2007

CK7+,
AMACR+,
CD10+,
Vim +

Renal cell tumours

Clear cell renal cell carcinoma	8310/3
Multilocular cystic renal neoplasm of low malignant potential	8316/1
Papillary renal cell carcinoma	8255/1
Hereditary leiomyomatosis and renal cell carcinoma (HLRCC)-associated renal cell carcinoma	8311/3*
Chromophobe renal cell carcinoma	8317/3
Collecting duct carcinoma	8319/3
Renal medullary carcinoma	8510/3
MiT Family translocation carcinomas	8311/3
Succinate dehydrogenase (SDH)-deficient renal carcinoma	8312/3
Mucinous tubular and spindle cell carcinoma	8480/3
Tubulocystic renal cell carcinoma	8316/3
Acquired cystic disease associated renal cell carcinoma	8316/3
Clear cell papillary renal cell carcinoma	8323/1
Renal cell carcinoma, unclassified	8312/3
Papillary adenoma	8260/0
Oncocytoma	8290/0

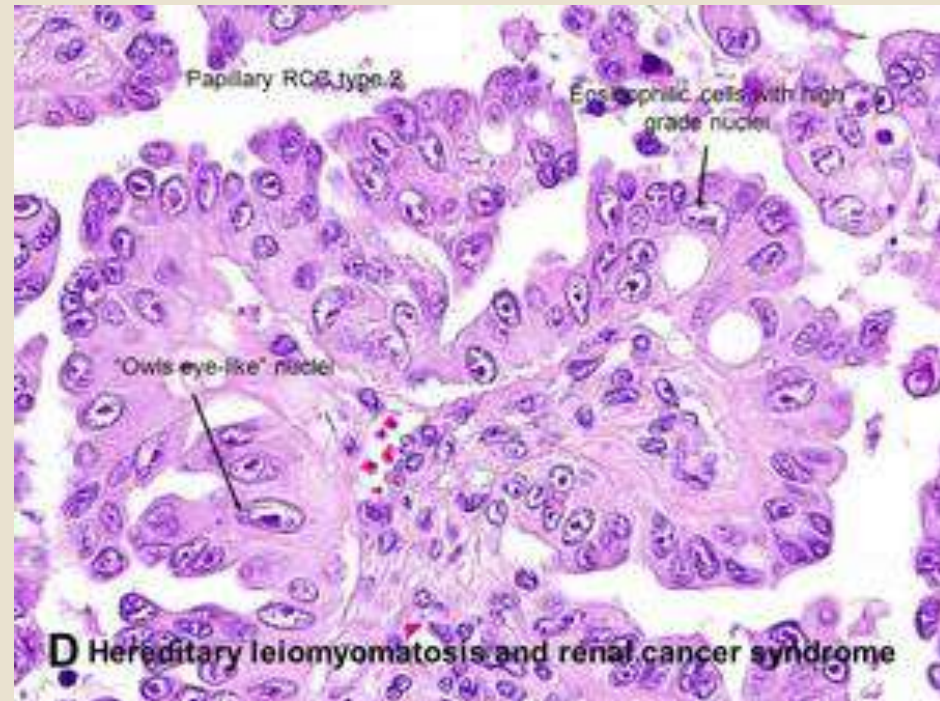


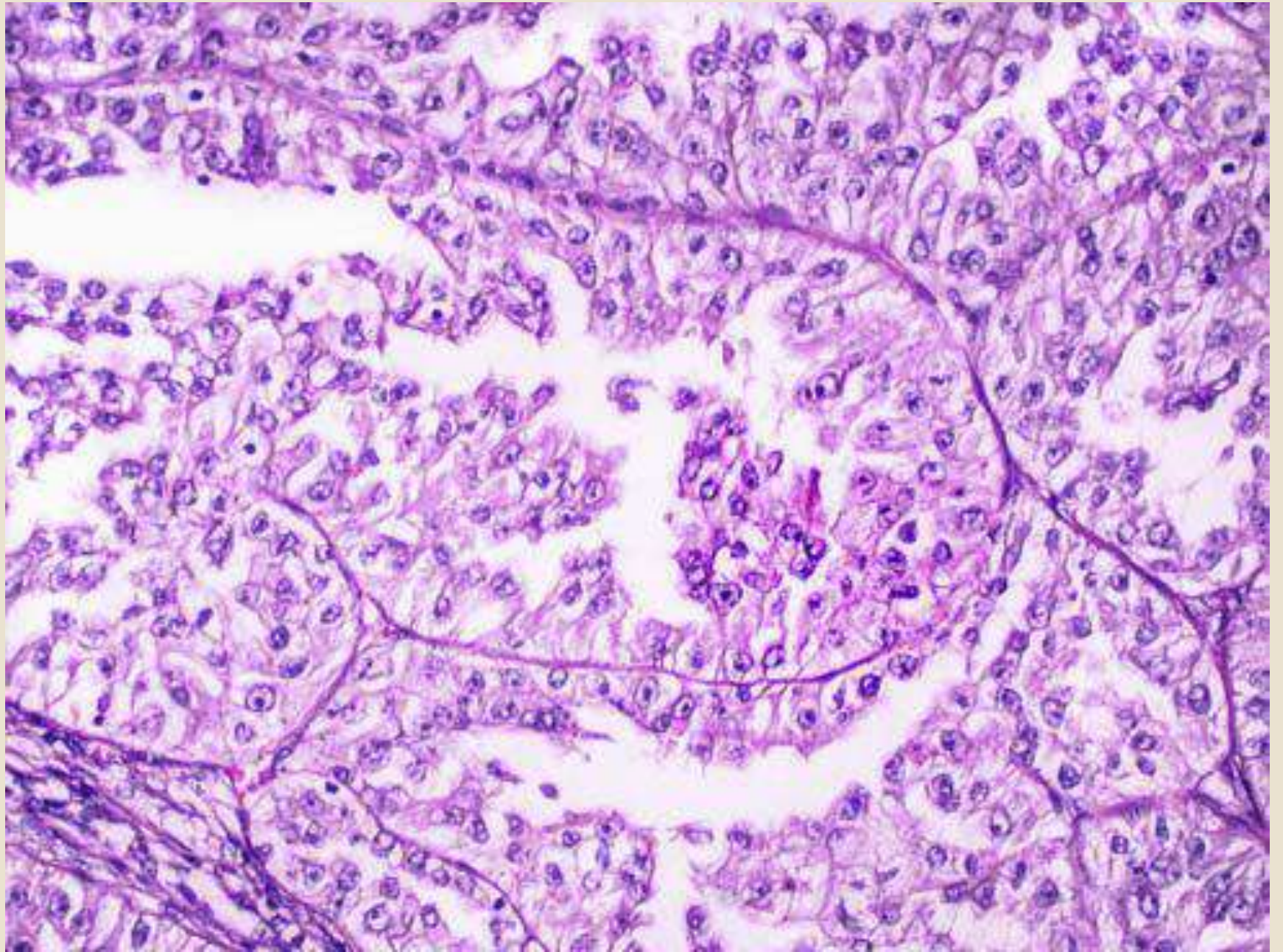
New entitie: Hereditary Leiomyomatosis and Renal Cell Carcinoma-Associated Renal Cell Carcinoma

Papillary type 2
Large cells with large
nucleus « CMV like »
aspects

Association with cutaneous
and uterine leiomyomas
(reed syndrom)

Therefore : clinical
informations ++



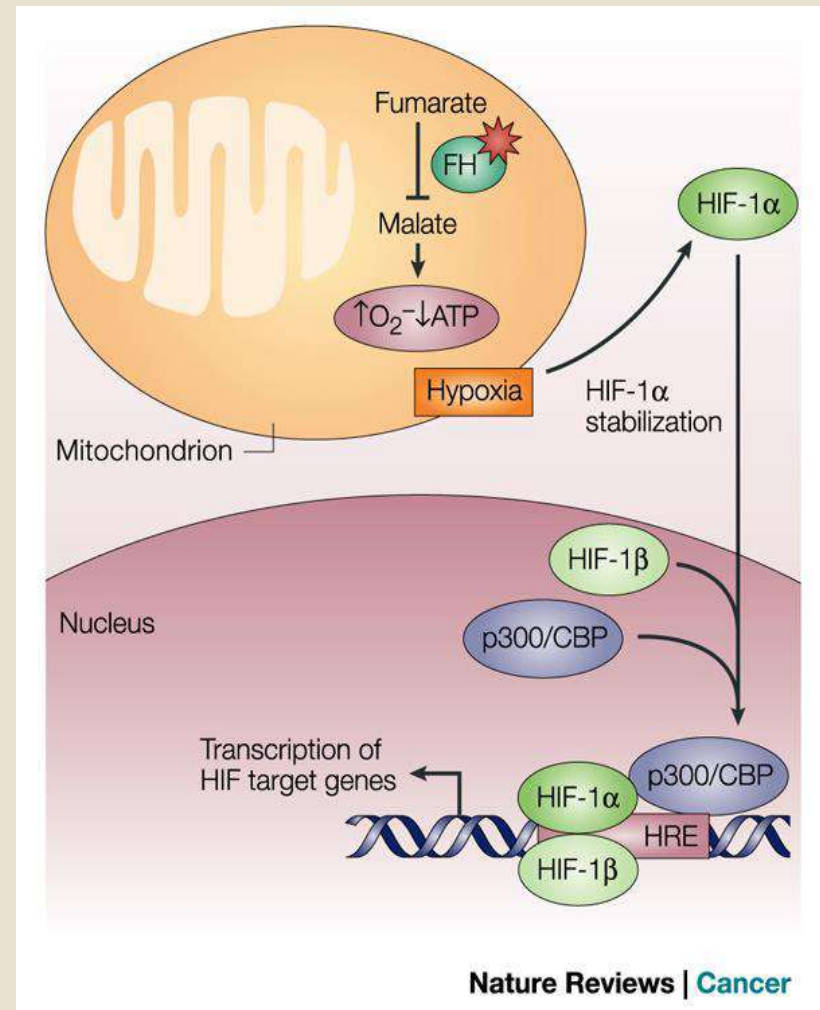


Hereditary leiomyomatosis and renal cell carcinoma-associated renal cell carcinoma

Dominant Autosomic Gene:
Chr 1q42.3-43 = fumarate hydratase (HIF/VHL metabolic pathway)

IHC : loss of FH expression

Poor prognosis
Early metastasis

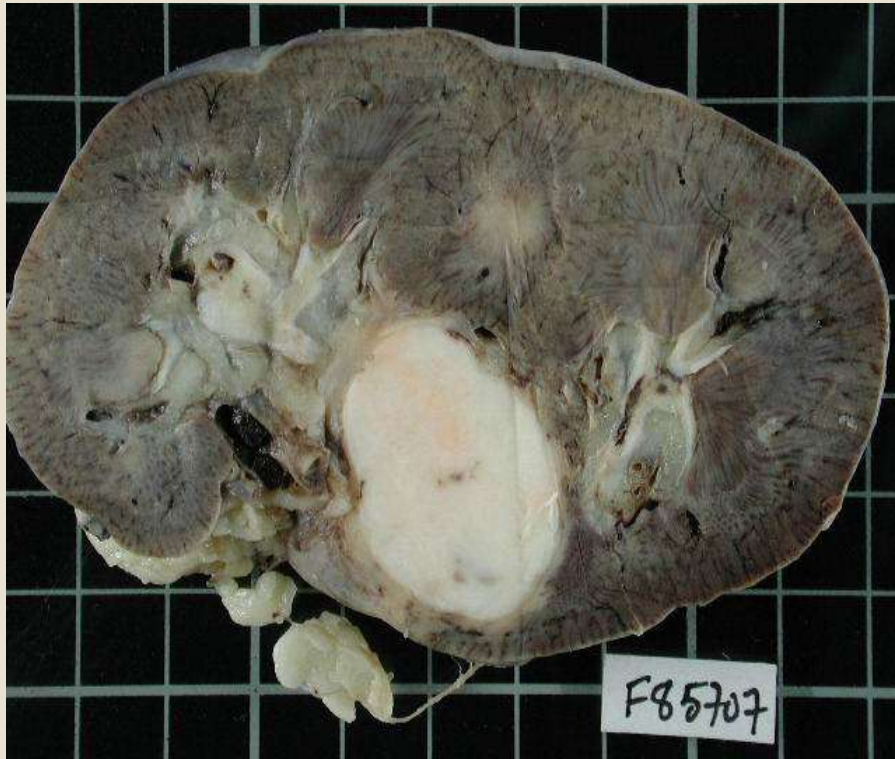


Renal cell tumours

Clear cell renal cell carcinoma	8310/3
Multilocular cystic renal neoplasm of low malignant potential	8316/1
Papillary renal cell carcinoma	8255/1
Hereditary leiomyomatosis and renal cell carcinoma (HLRCC)-associated renal cell carcinoma	8311/3*
Chromophobe renal cell carcinoma	8317/3
Collecting duct carcinoma	8319/3
Renal medullary carcinoma	8510/3
MiT Family translocation carcinomas	8311/3
Succinate dehydrogenase (SDH)-deficient renal carcinoma	8312/3
Mucinous tubular and spindle cell carcinoma	8480/3
Tubulocystic renal cell carcinoma	8316/3
Acquired cystic disease associated renal cell carcinoma	8316/3
Clear cell papillary renal cell carcinoma	8323/1
Renal cell carcinoma, unclassified	8312/3
Papillary adenoma	8260/0
Oncocytoma	8290/0



Mucinous tubular and spindle cell renal carcinoma



Mean age 50 years
Male to female ratio 1:3

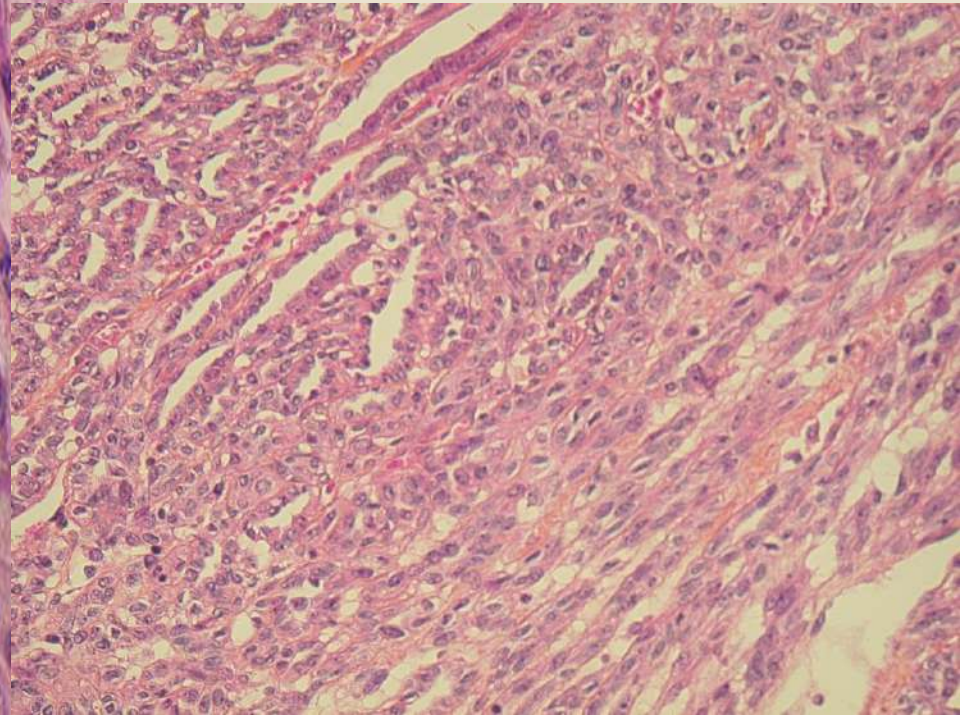
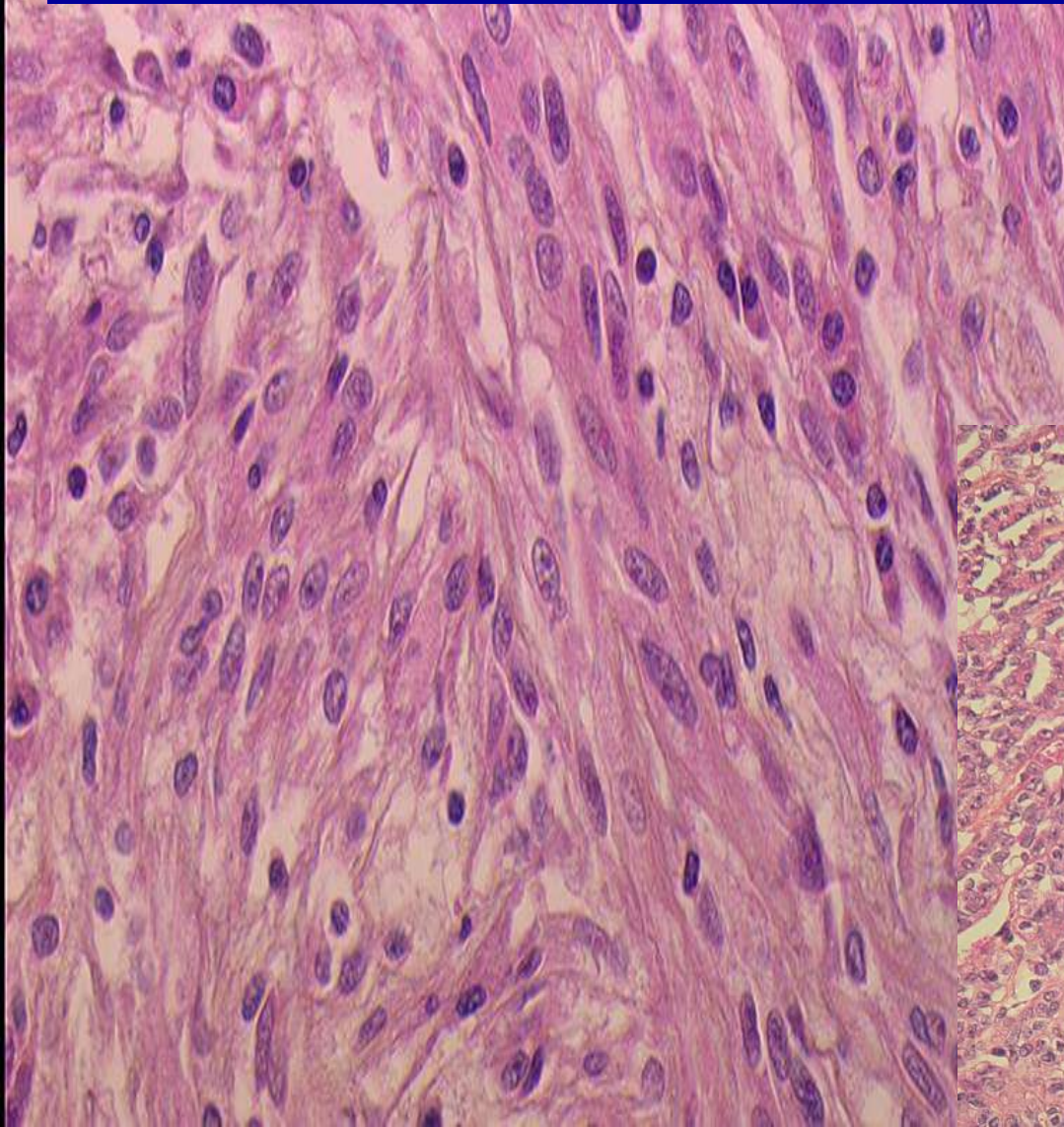
Well delimited
Whitish or gray

Usually
No Necrosis and hemorrhage

Mucinous tubular and spindle cell Carcinoma

Regular spindle cells
arranged in sheets

Cuboidal regular cells
arranged in cords
tubules and papillae

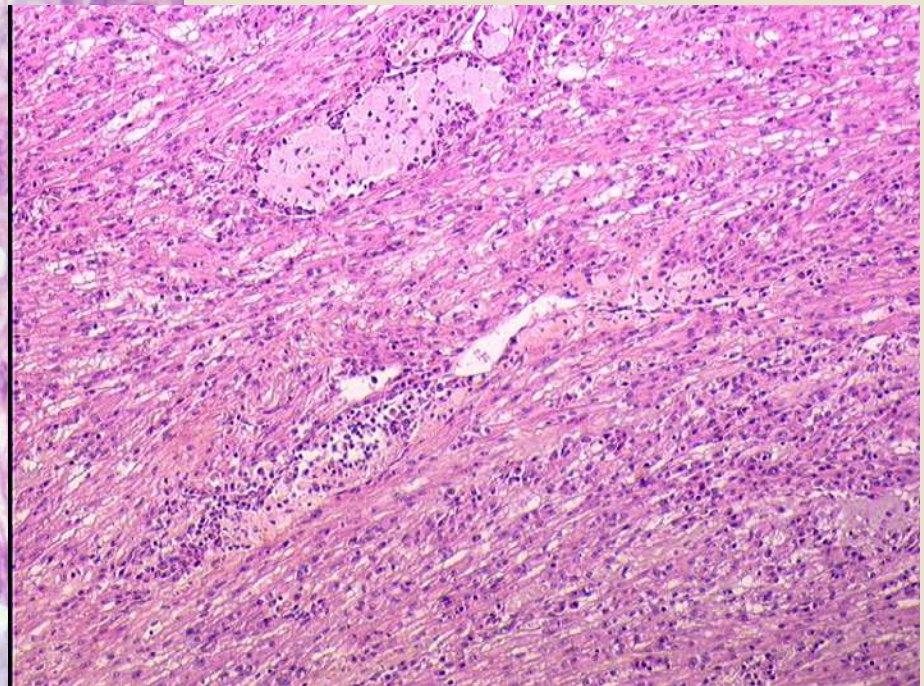
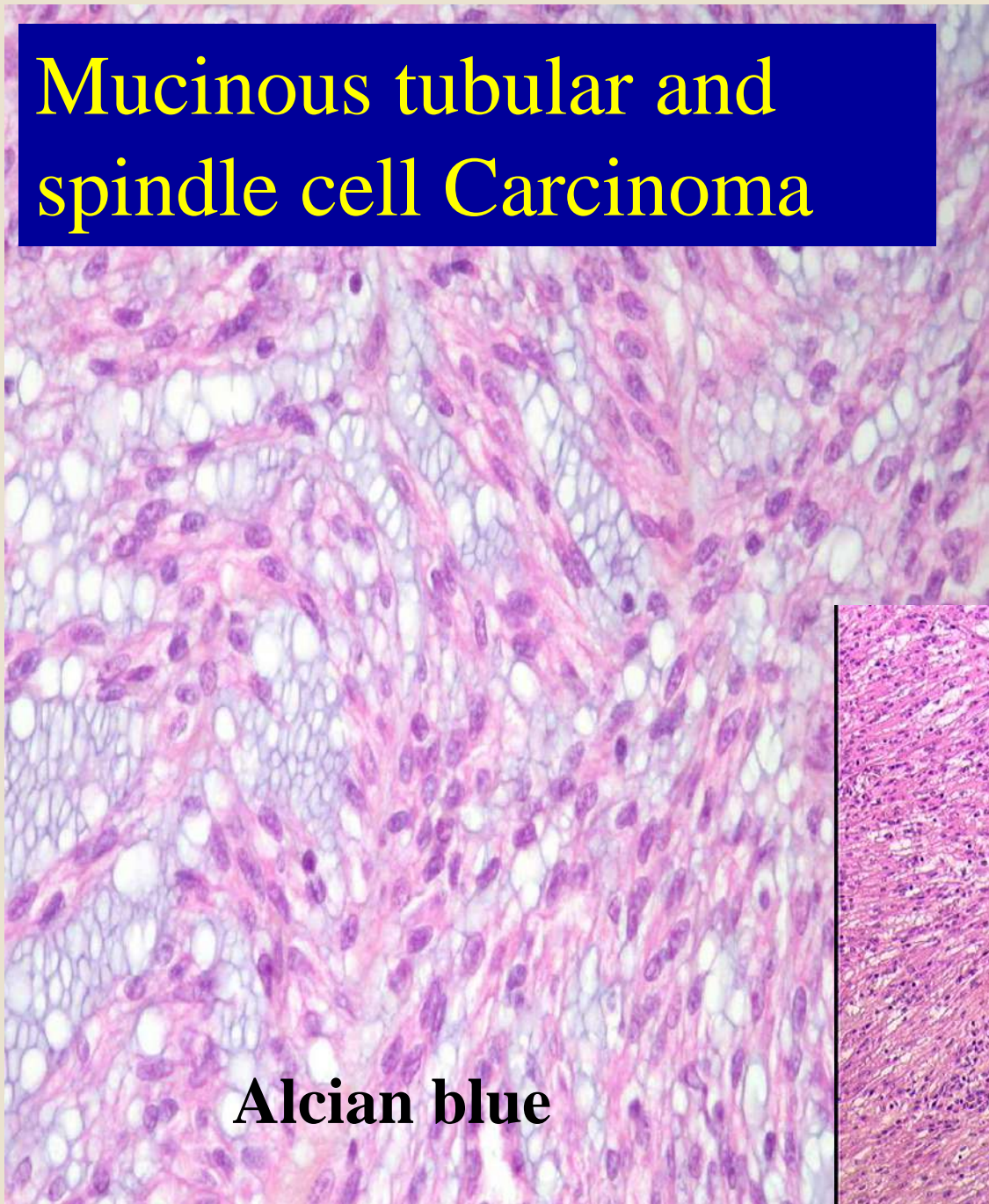


Mucinous tubular and spindle cell Carcinoma

myxoid stroma (alcian blue +)

clusters of foamy cells

Alcian blue



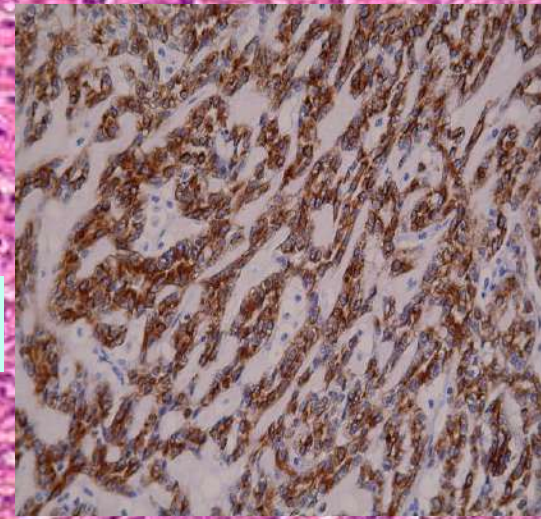
Mucinous tubular and spindle cell Carcinoma

KL1 + AE1/AE3 + EMA +
CK 7 +, CK19 +
AMACR +
E-cadherine +
Vimentin -, CD 10 -

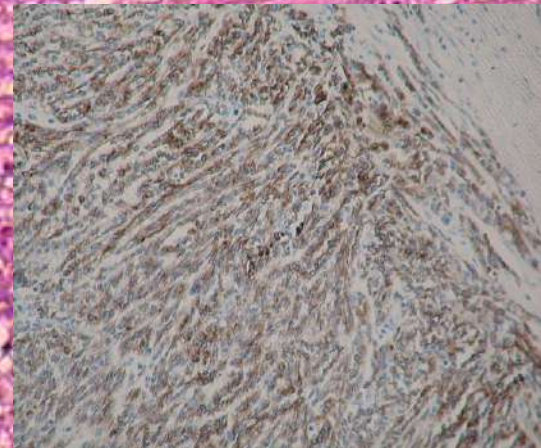
Low grade

Multiple chromosomic loss
(1, 4, 6, 8, 13, 14, 15 , 18)
No 3p-
No 7+ nor 17+

CK19



CK7



Expanding the Histologic Spectrum of Mucinous Tubular and Spindle Cell Carcinoma of the Kidney

Samson W. Fine, MD,* Pedram Argani, MD,† Angelo M. DeMarzo, MD, PhD,†
Brett Delahant, MD,‡ Thomas J. Sebo, MD,§ Victor E. Reuter, MD,*
and Jonathan I. Epstein, MD†

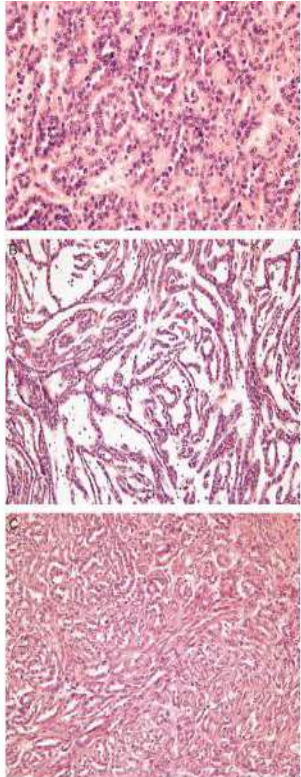


FIGURE 1. "Classic" MTSC with short tubules set in a myxoid matrix (A), cellular cords and tubules in abundant mucinous matrix (B), or transitions between tubular and spindle morphology (C).

DISCUSSION

Mucinous, tubular, and spindle cell carcinoma is a rare, recently described variant of RCC whose true

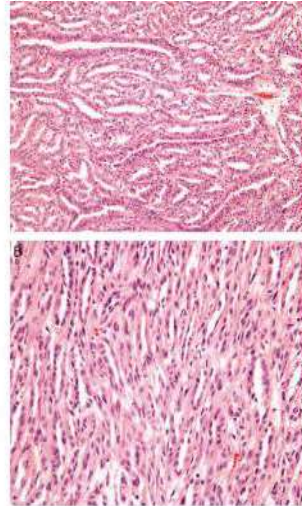


FIGURE 2. "Mucin-poor" MTSC with elongated to serpentine tubules (A); transitions from tubular to spindle morphology (B).

incidence is not yet established. These lesions have received increasing attention owing to recognition of apparently low-grade distal nephron-derived carcinomas,^{1,2,19,24,25,30-33} and their reported overall favorable prognosis.^{7,15,24,30} According to the 2004 WHO classification of renal tumors, these tumors are composed of tightly packed, small, elongated tubules with transitions to a spindle cell configuration, separated by pale mucinous stroma, hence the name "mucinous tubular and spindle cell carcinoma."²⁹ Although the notion that any 1 of the 3 MTSC components may focally predominate has been previously observed,^{18,24,30,31} this series is the first to document cases of MTSC with widespread absence of the mucinous/myxoid component and confirm these findings histochemically. As most regard the typically abundant extracellular matrix as a key to MTSC diagnosis,^{5,14,23} its absence makes accurate diagnosis of this entity more challenging. These difficulties are compounded in tumors with "mucin-poor" histology and either tubular predominance or spindle-cell

Mucinous tubular and spindle cell carcinoma of kidney are excluded from papillary renal cell carcinomas

S.S. Sen et al. / *Annals of Diagnostic Pathology 11 (2007) 13-21*

17

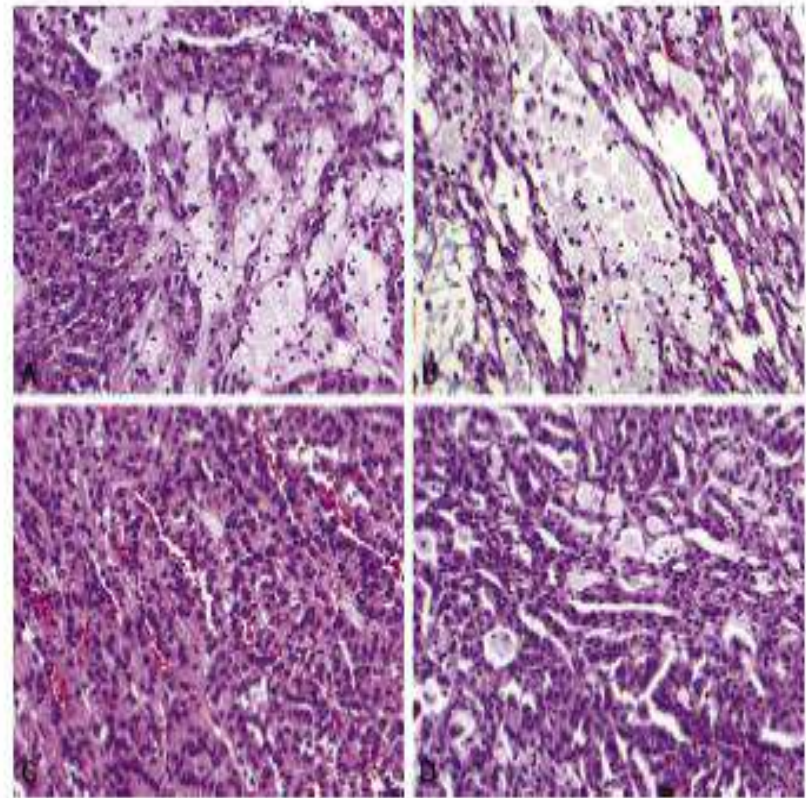


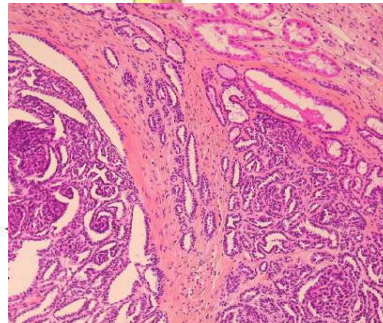
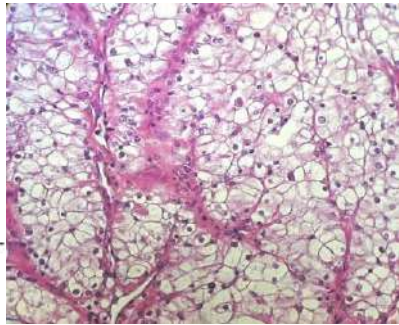
Fig. 4. Presence of clusters or nests of foamy macrophages within spindle cell areas (A, original magnification $\times 200$), within tubular areas (B, original magnification $\times 200$), and within focally compressed tubulopapillary areas of the tumor (C and D, original magnification $\times 200$).



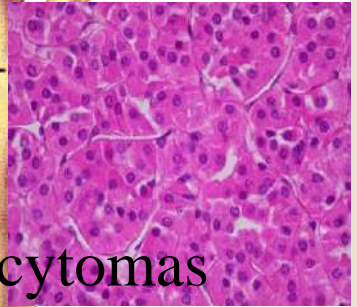
Clear cells

Papillary RCC

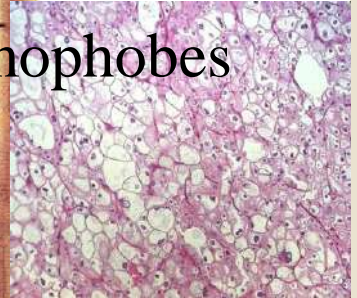
CK7-, CD117-,
CD10-; EMA+
-1;-Y;



Oncocytomas



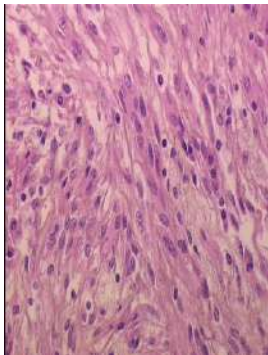
Chromophobes
RCC



CK7-, CD10+ VIM +
3p25-26-

CK7+, CD10+ VIM +
+7;+17


CK7+, CD117+,
VIM + EMA+
-1;-2;-6;-10;-Y



Mucinous TSC RCC

Renal cell tumours

Clear cell renal cell carcinoma	8310/3
Multilocular cystic renal neoplasm of low malignant potential	8316/1
Papillary renal cell carcinoma	8255/1
Hereditary leiomyomatosis and renal cell carcinoma (HLRCC)-associated renal cell carcinoma	8311/3*
Chromophobe renal cell carcinoma	8317/3
Collecting duct carcinoma	8319/3
Renal medullary carcinoma	8510/3
MiT Family translocation carcinomas	8311/3
Succinate dehydrogenase (SDH)-deficient renal carcinoma	8312/3
Mucinous tubular and spindle cell carcinoma	8480/3
Tubulocystic renal cell carcinoma	8316/3
Acquired cystic disease associated renal cell carcinoma	8316/3
Clear cell papillary renal cell carcinoma	8323/1
Renal cell carcinoma, unclassified	8312/3
Papillary adenoma	8260/0
Oncocytoma	8290/0





Chromophobe Carcinoma

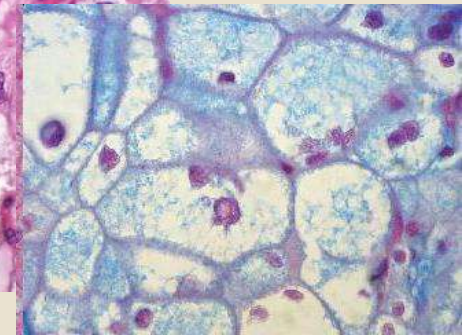
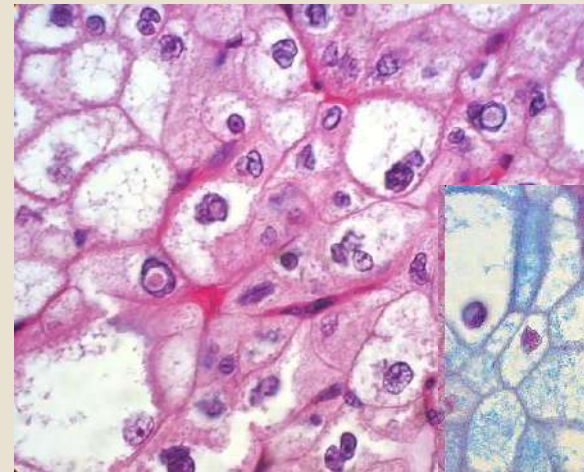
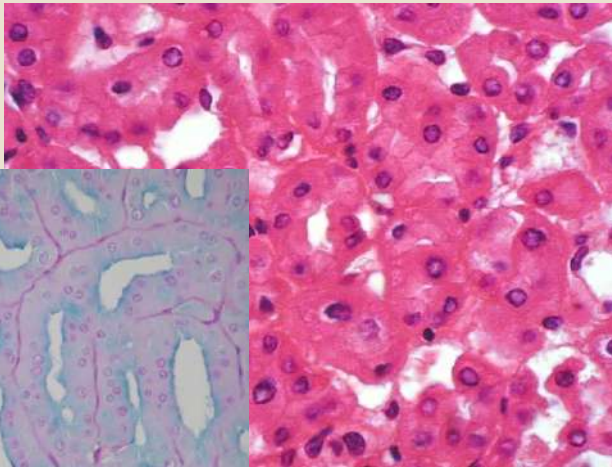
15% of renal tumours

Oncocytomatosis, Birt-Hogg-Dube

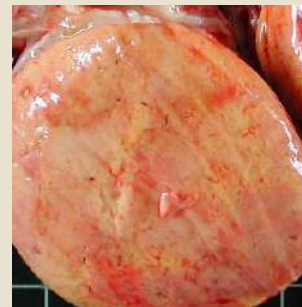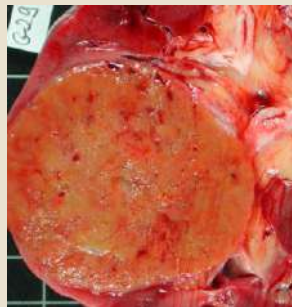
Main problem : Differencial Diagnosis Oncocytoma / Chromophobe RCC

Oncocytoma

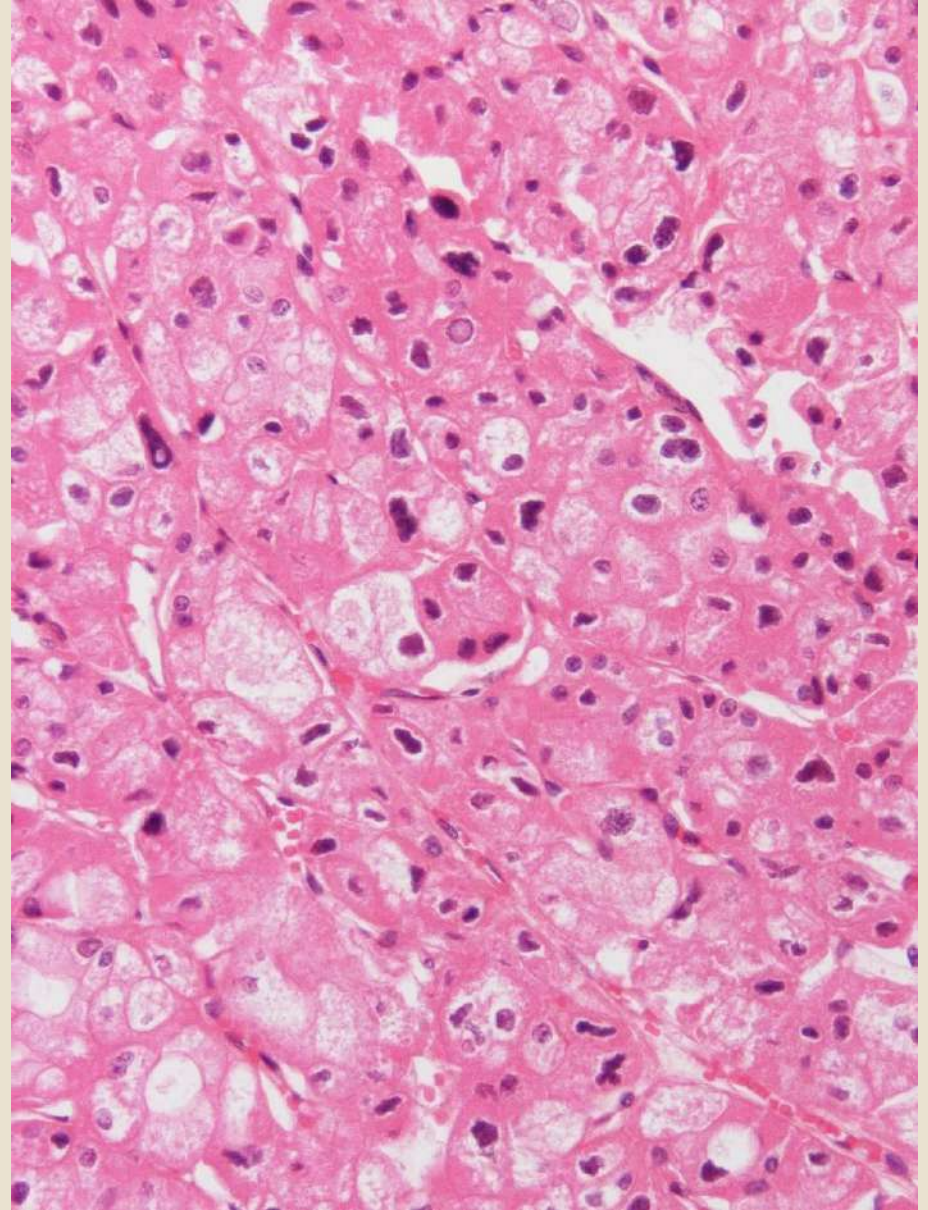
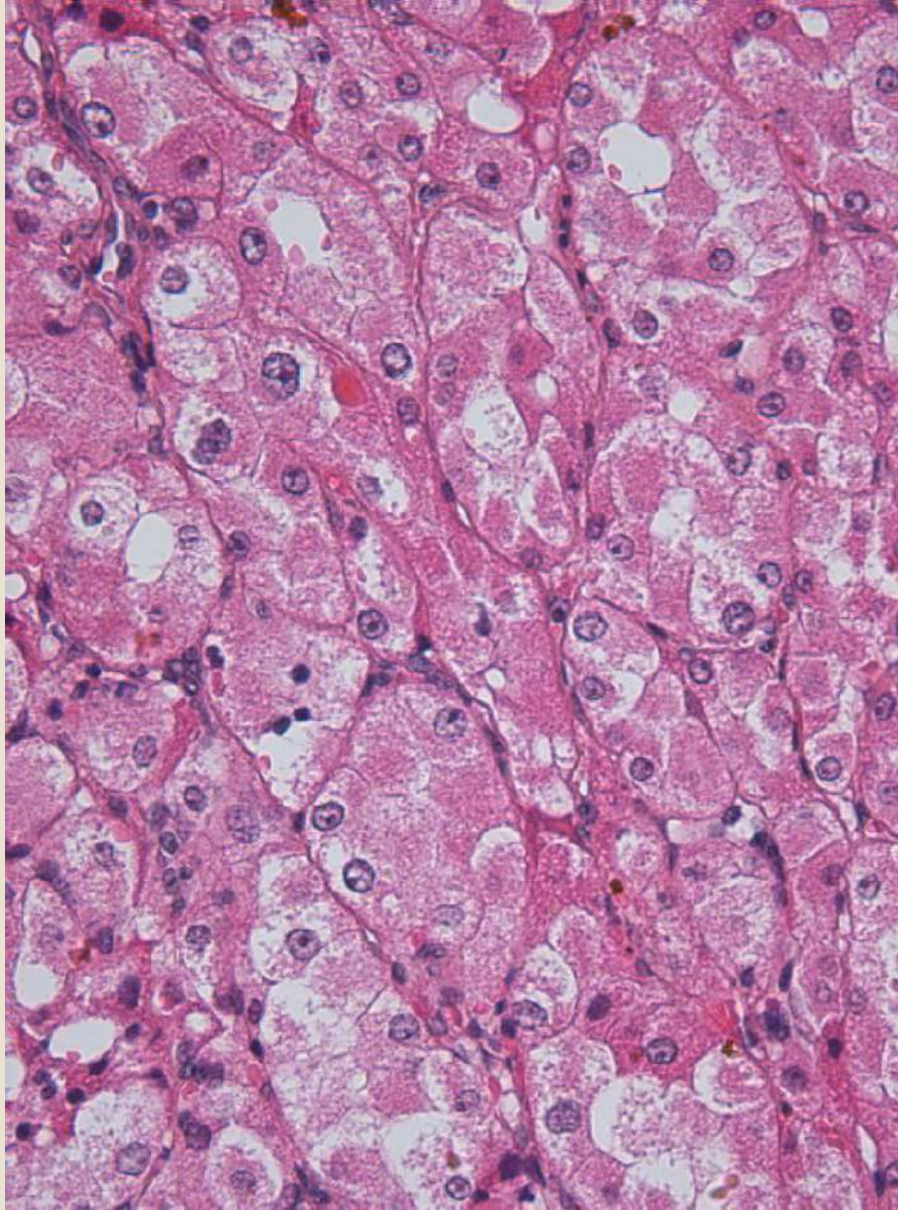
Chromophobe carcinoma



Hale apical
CK7 -/+
EMA -/+
C-kit +/-
E-cadhérine +/-
Vimentine -
Chromosome 1, Y

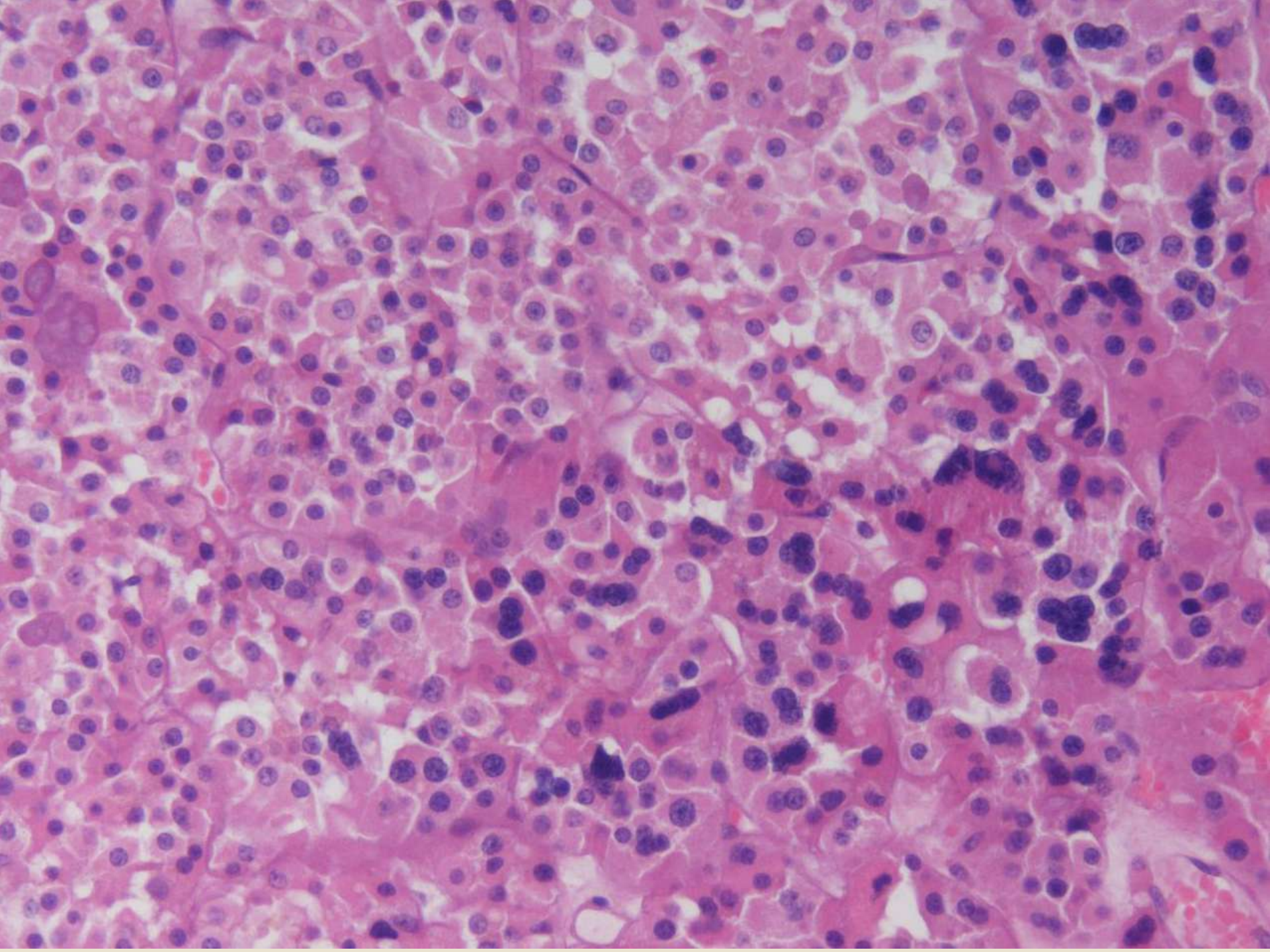


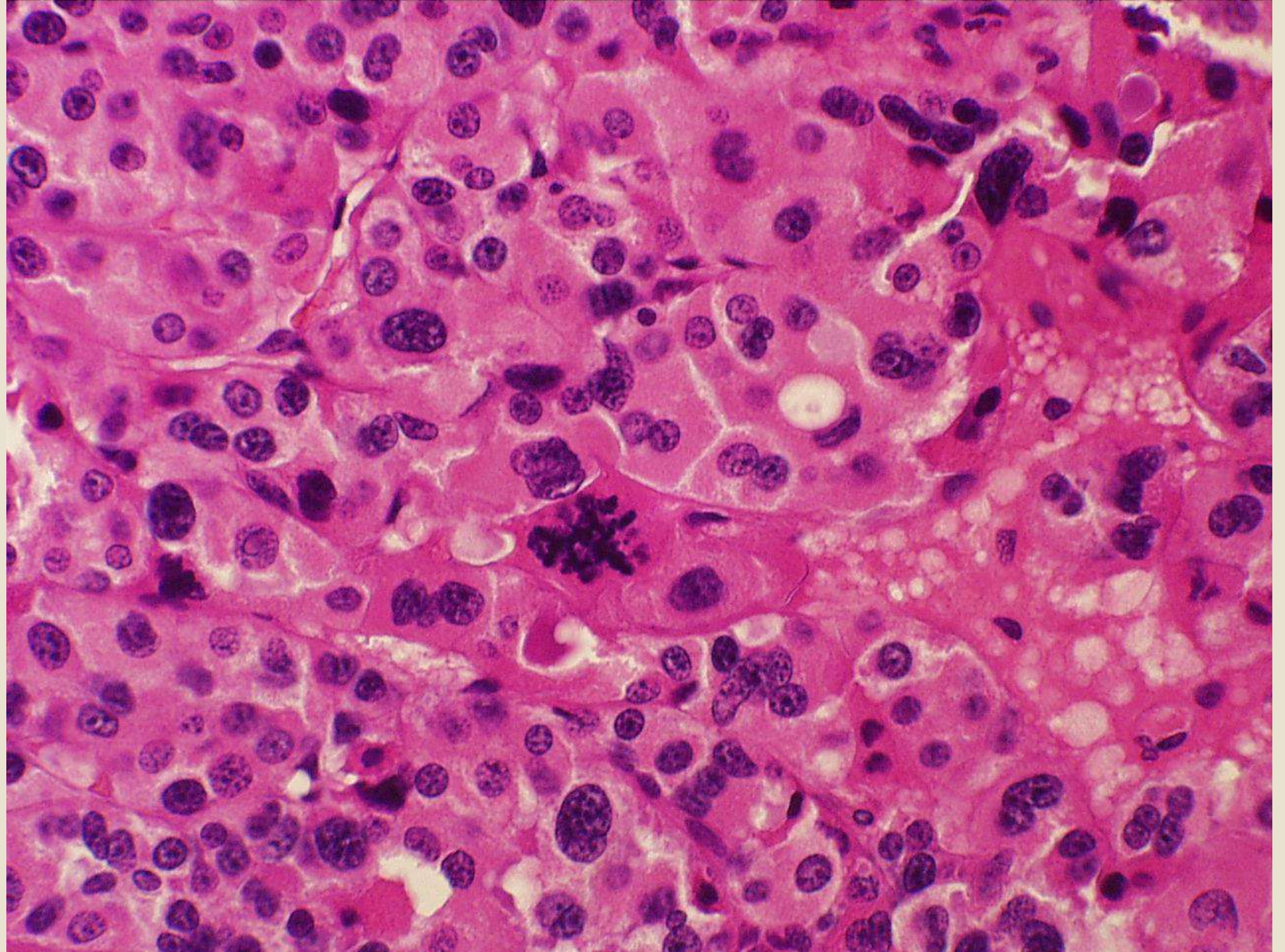
Hale cytoplasm
CK7 +
EMA +
C-kit +/-
E-cadhérine +/-
Vimentine +
Multiple Chromosome loss

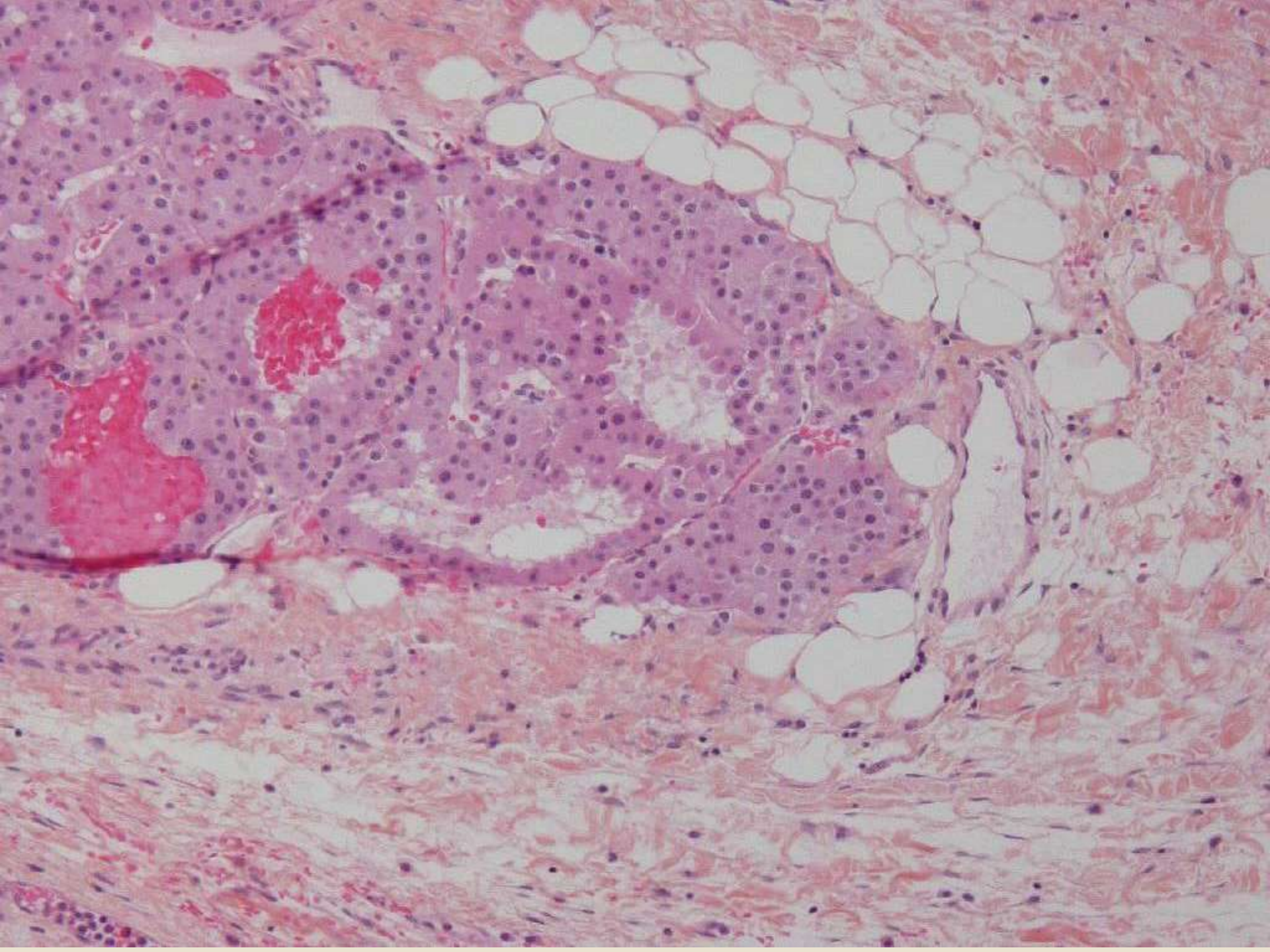


Oncoyctomas : atypical aspects possibles

- possible
 - atypias
 - binucleation
 - Atypical mitosis
 - Necrosis
 - clear cells <5%
- « permissible atypical features »







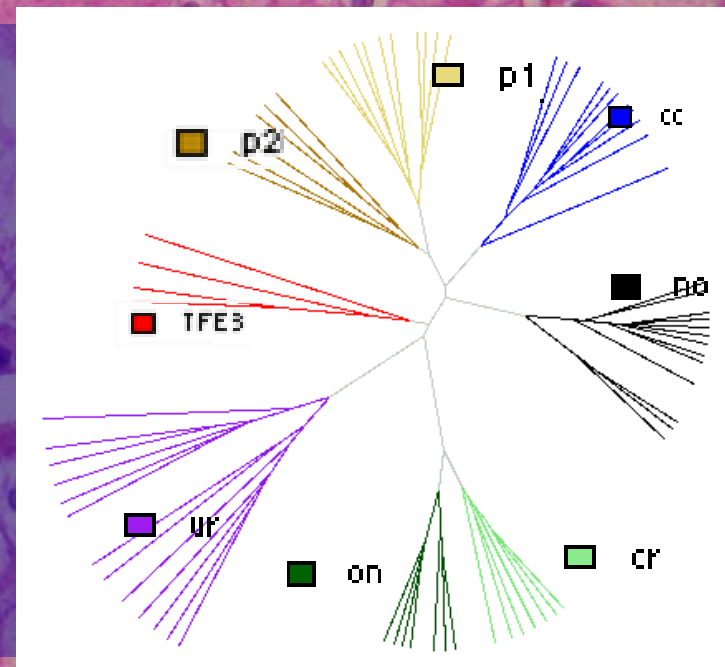
Oncocytoma & chromophobe Carcinoma, Oncocytomatosis, Birt-Hogg-Dube syndrom

A molecular spectrum of lesion

Oncocytoma benign

Chromophobe carcinoma malignant

If multiple tumours especially
ChRCC, investigate for BHD
syndrom



Birt-Hogg-Dubé

BHD : 17p11.2 (folliculin)

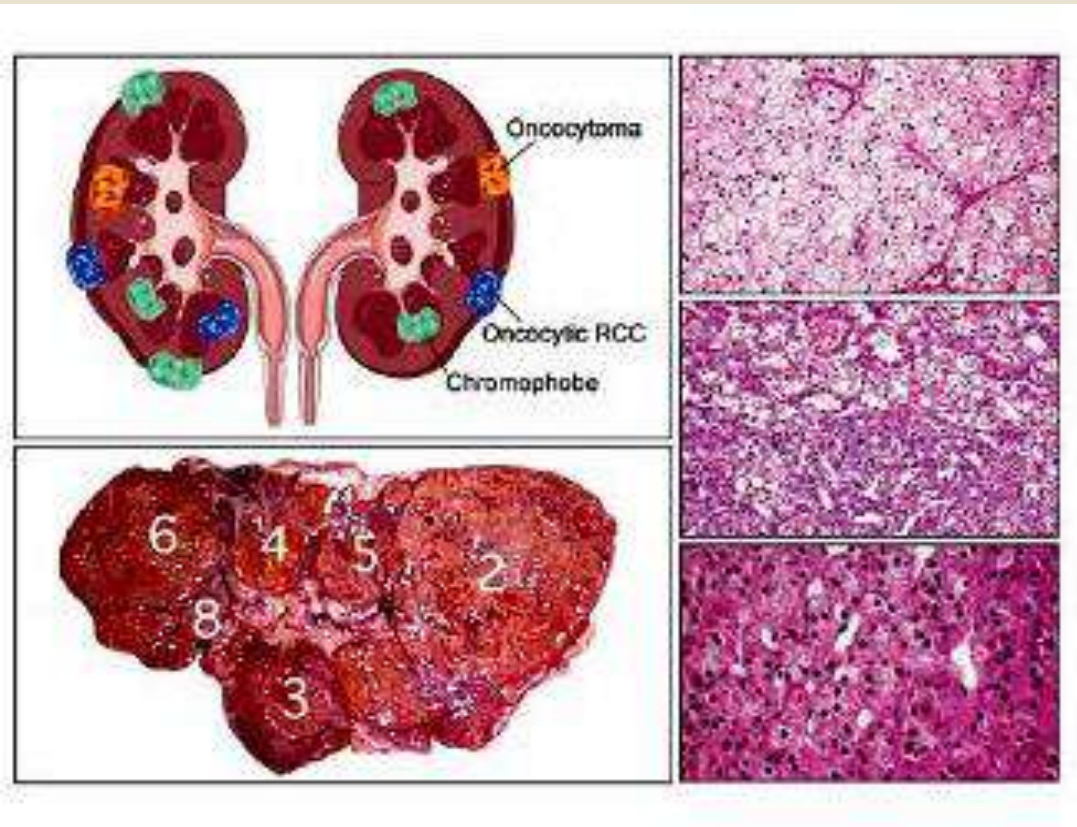
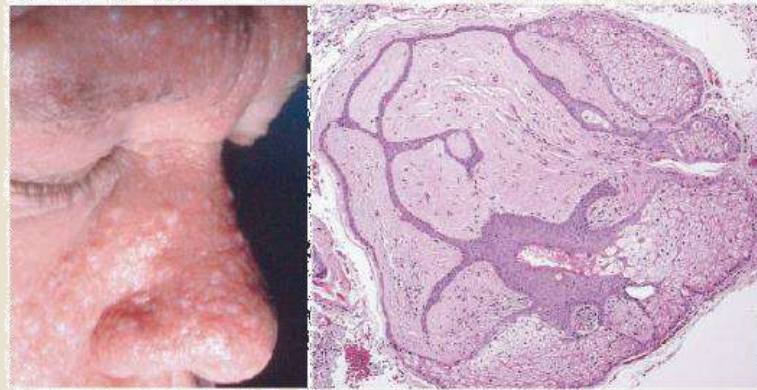
Dominant autosomal

Benign skin tumors
(fibrofolliculomas)

Spontaneous Pneumothorax

Oncocytomas, chromophobes
carcinomas, multiple
tumours, hybrid tumours

Other Renal carcinomas



Renal cell tumours

Clear cell renal cell carcinoma	8310/3
Multilocular cystic renal neoplasm of low malignant potential	8316/1
Papillary renal cell carcinoma	8255/1
Hereditary leiomyomatosis and renal cell carcinoma (HLRCC)-associated renal cell carcinoma	8311/3*
Chromophobe renal cell carcinoma	8317/3
Collecting duct carcinoma	8319/3
Renal medullary carcinoma	8510/3
MiT Family translocation carcinomas	8311/3
Succinate dehydrogenase (SDH)-deficient renal carcinoma	8312/3
Mucinous tubular and spindle cell carcinoma	8480/3
Tubulocystic renal cell carcinoma	8316/3
Acquired cystic disease associated renal cell carcinoma	8316/3
Clear cell papillary renal cell carcinoma	8323/1
Renal cell carcinoma, unclassified	8312/3
Papillary adenoma	8260/0
Oncocytoma	8290/0

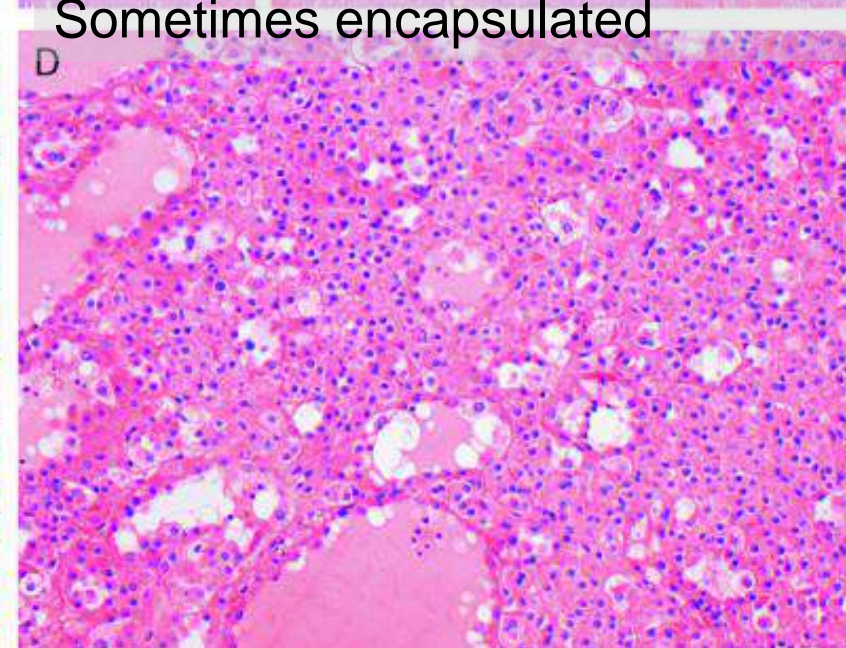
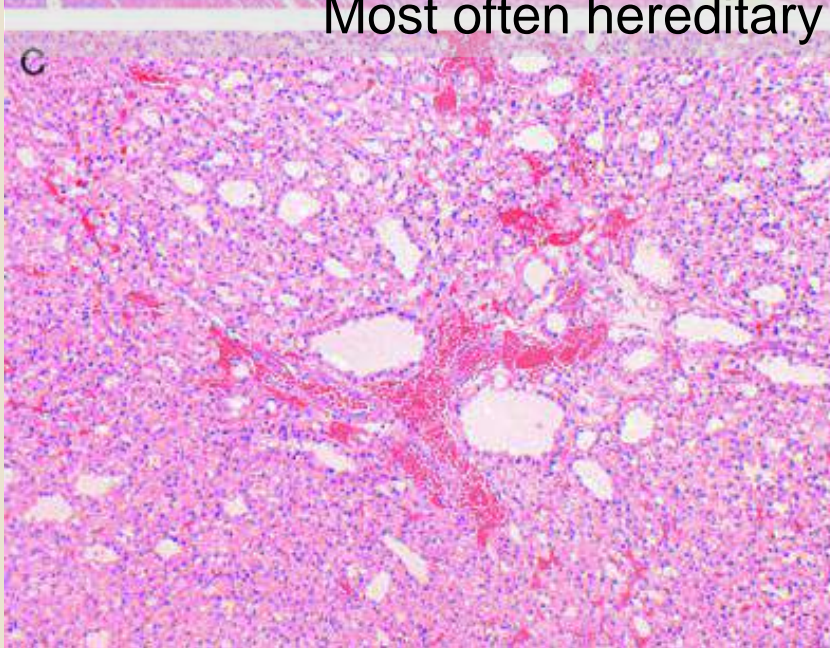
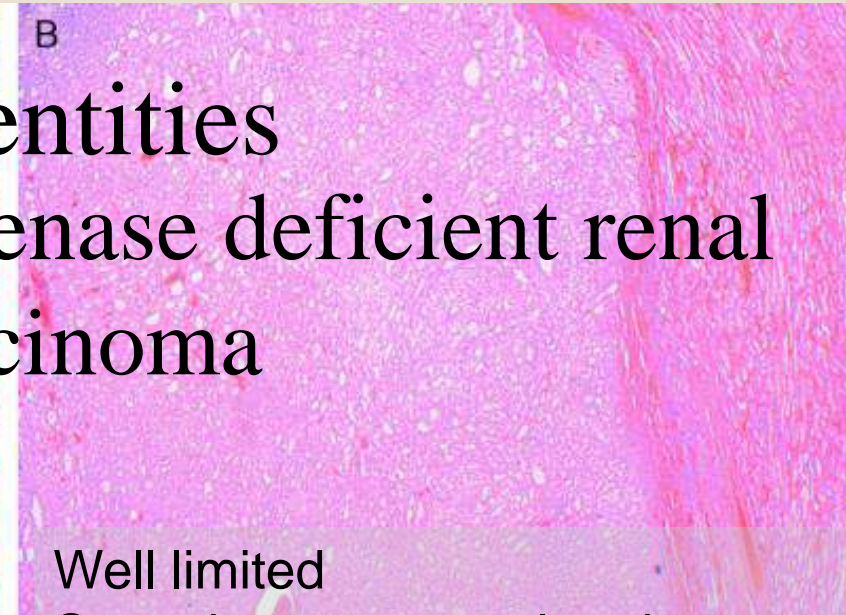
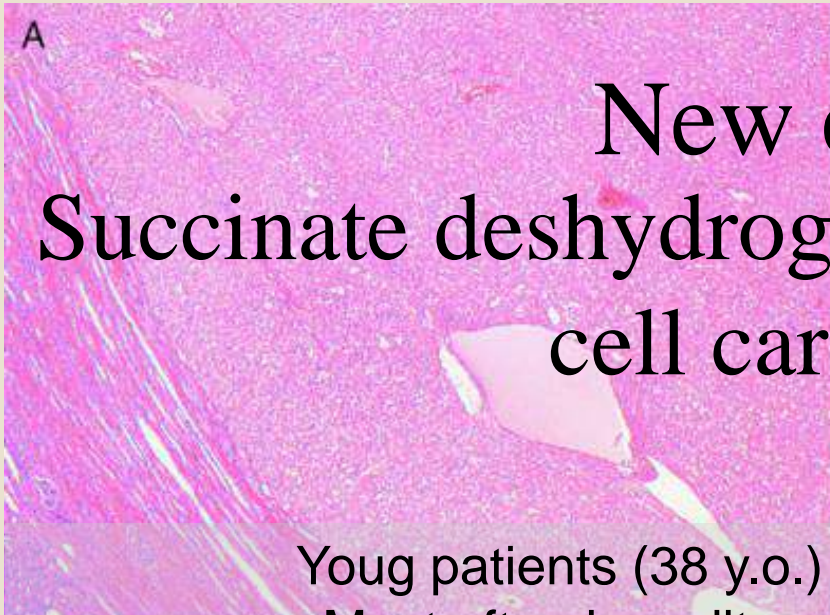


New entities

Succinate deshydrogenase deficient renal cell carcinoma

Young patients (38 y.o.)
Most often hereditary

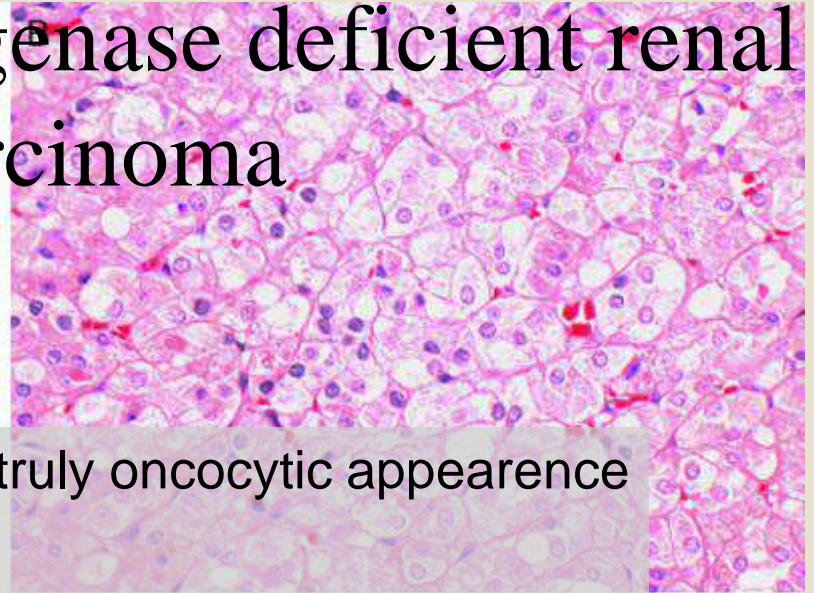
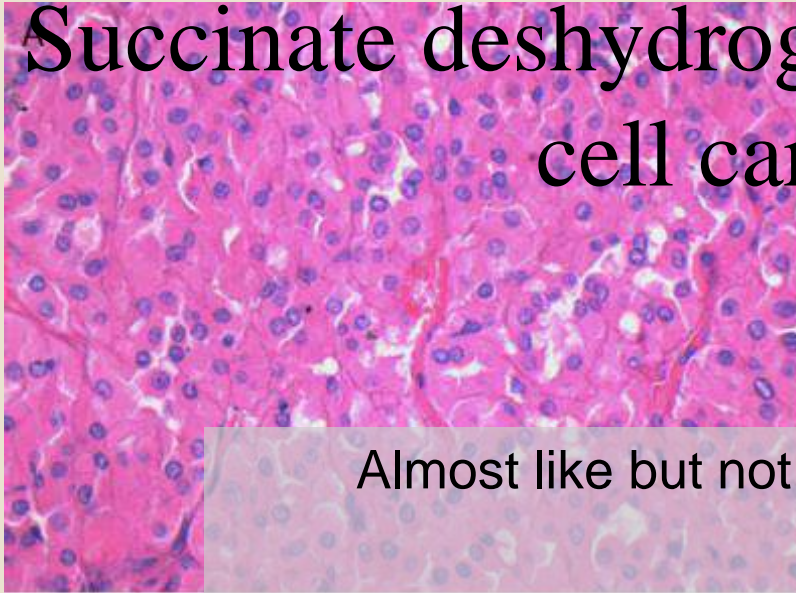Well limited
Sometimes encapsulated



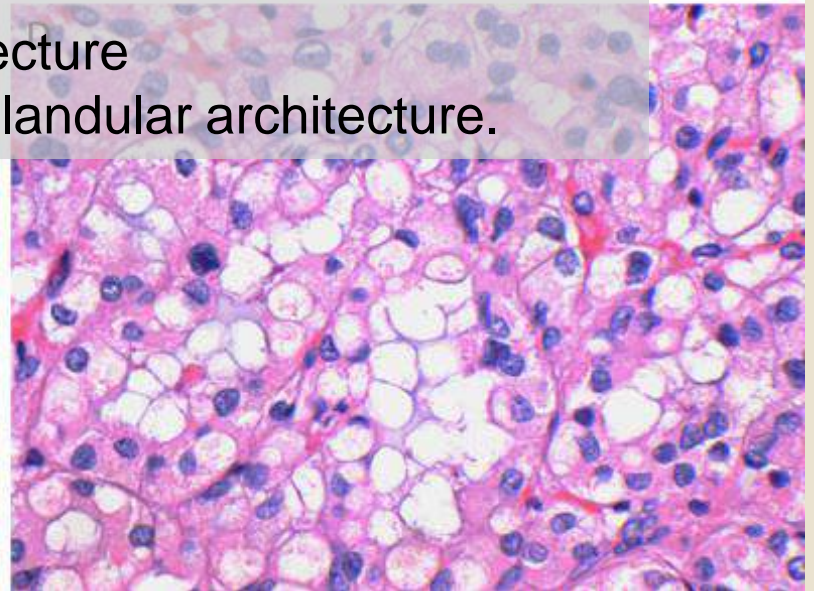
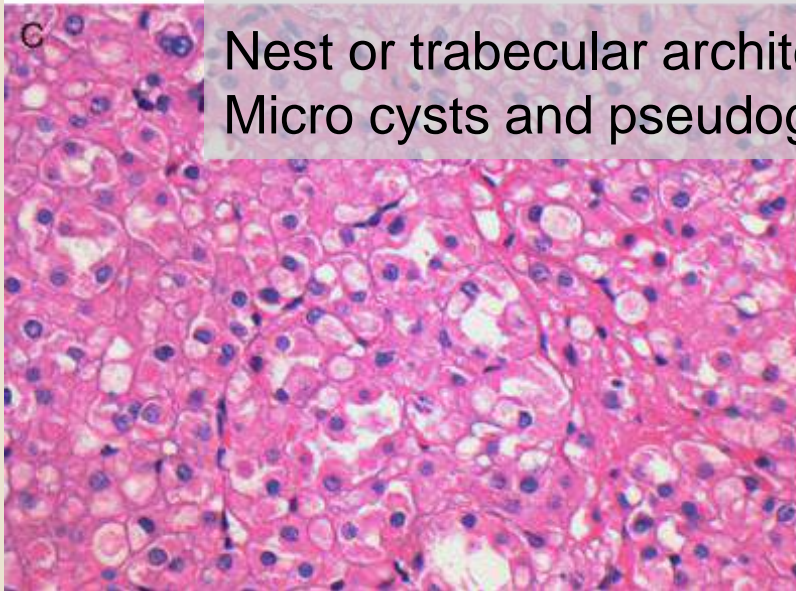
Succinate Dehydrogenase B mutation associated RCC

- « hereditary paraganglioma-pheochromocytoma syndrome » (PGL/PC) : rare
- Stromal tumors (GIST) : rare
- Tumors unencapsulated
- 0,02 to 0,5% of renal tumor

Succinate dehydrogenase deficient renal cell carcinoma



Almost like but not truly oncocytic appearance



Nest or trabecular architecture
Micro cysts and pseudoglandular architecture.

Succinate deshydrogenase deficient renal cell carcinoma

Germ cell mutations of SDH-B (most often)
Risk to develop renal neoplasia 14%

IHC : SDH-B - (but SDH-A and C +)
CK7 – c-kit +/- (focally)
Pax8 and E-Cadh « always » +

Prognosis good but few cases and short follow up

DD : Oncocytoma

Am J Surg Pathol. 2014 Dec;38(12):1588-602

Renal cell tumours

Clear cell renal cell carcinoma	8310/3
Multilocular cystic renal neoplasm of low malignant potential	8316/1
Papillary renal cell carcinoma	8255/1
Hereditary leiomyomatosis and renal cell carcinoma (HLRCC)-associated renal cell carcinoma	8311/3*
Chromophobe renal cell carcinoma	8317/3
Collecting duct carcinoma	8319/3
Renal medullary carcinoma	8510/3
MiT Family translocation carcinomas	8311/3
Succinate dehydrogenase (SDH)-deficient renal carcinoma	8312/3
Mucinous tubular and spindle cell carcinoma	8480/3
Tubulocystic renal cell carcinoma	8316/3
Acquired cystic disease associated renal cell carcinoma	8316/3
Clear cell papillary renal cell carcinoma	8323/1
Renal cell carcinoma, unclassified	8312/3
Papillary adenoma	8260/0
Oncocytoma	8290/0



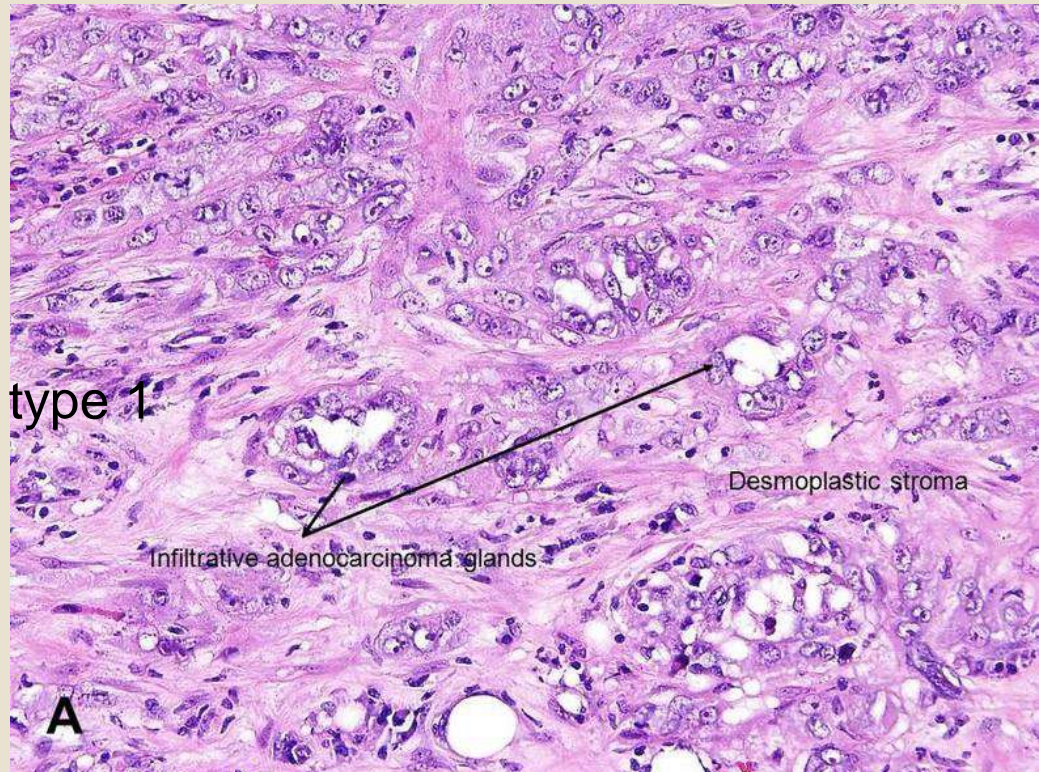
Collecting duct Carcinoma

Medullary located tumors
With infiltrative and irregular fibrous
borders
Irregular glands and trabeculae
High nuclear grade

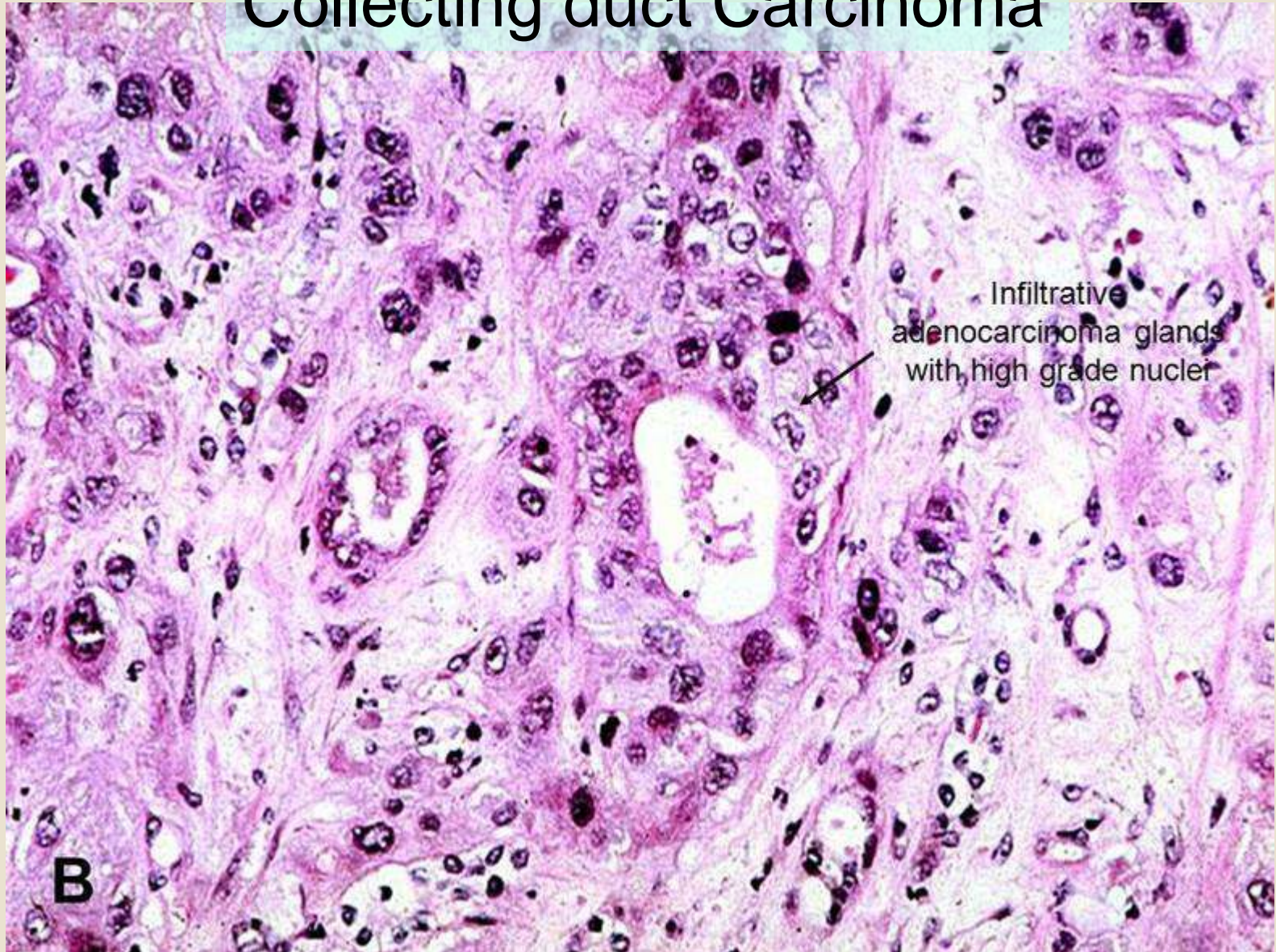
CK7+,
AMACR+,
INI1+

DD : Tubulopapillary non type 1
Metastasis
Medullary carcinoma

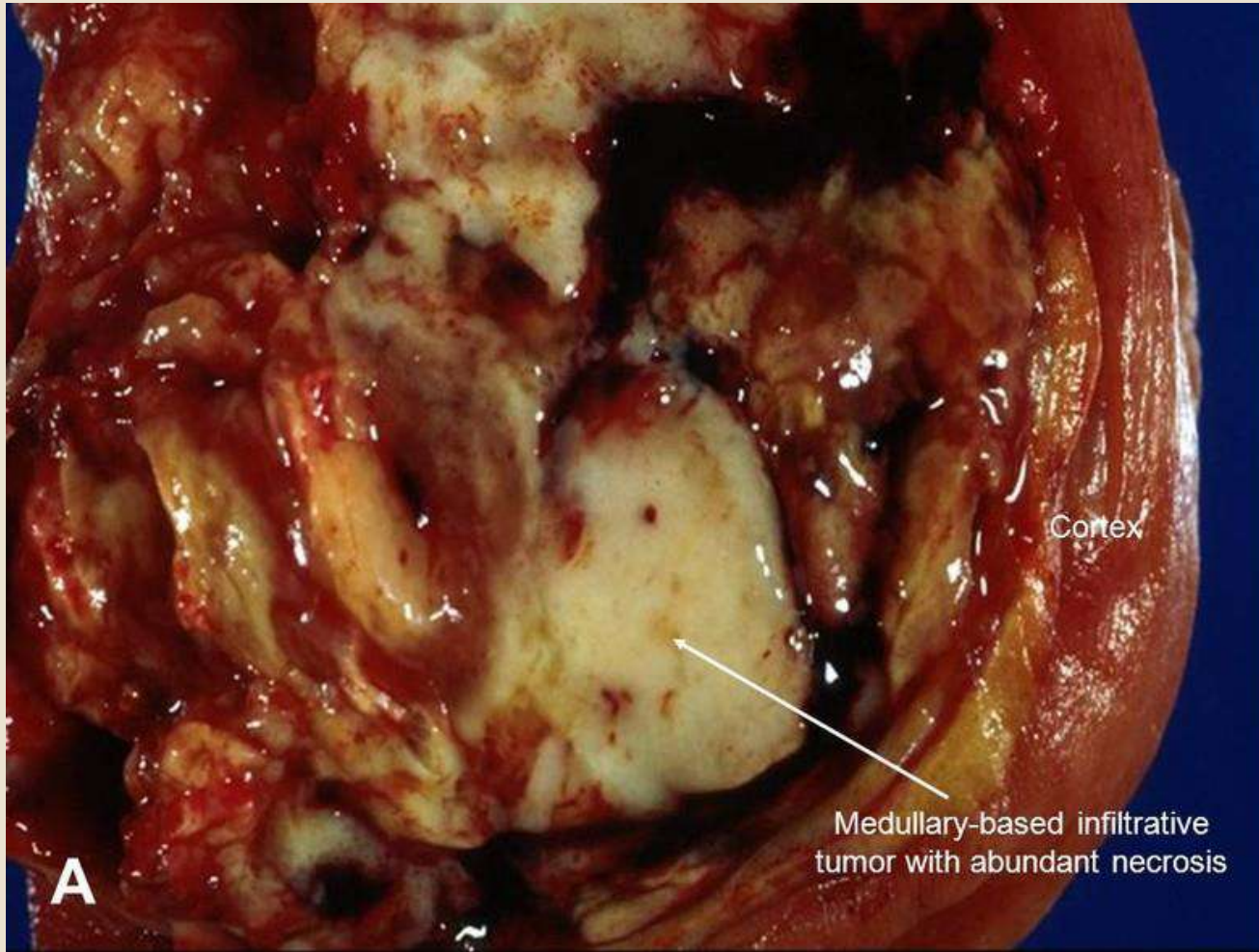
Aggressive tumors



Collecting duct Carcinoma

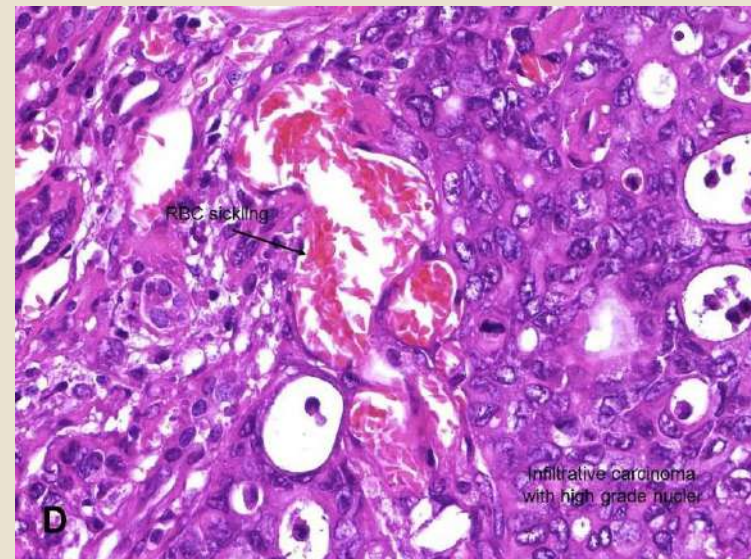
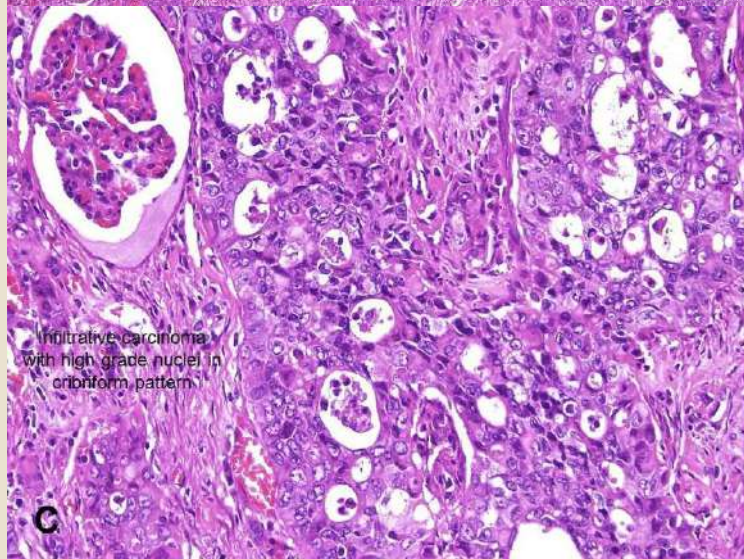
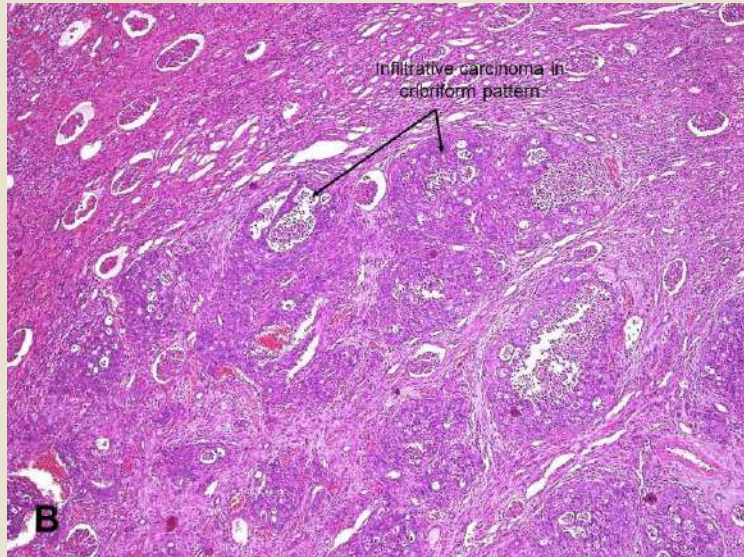


Medullary Carcinoma



Young adults with sickle cell disease

Medullary Carcinoma



Young adults with sickle cell disease

Irregular shaped glands in dense fibrous stroma

Sickle cells can be seen

INI1 -

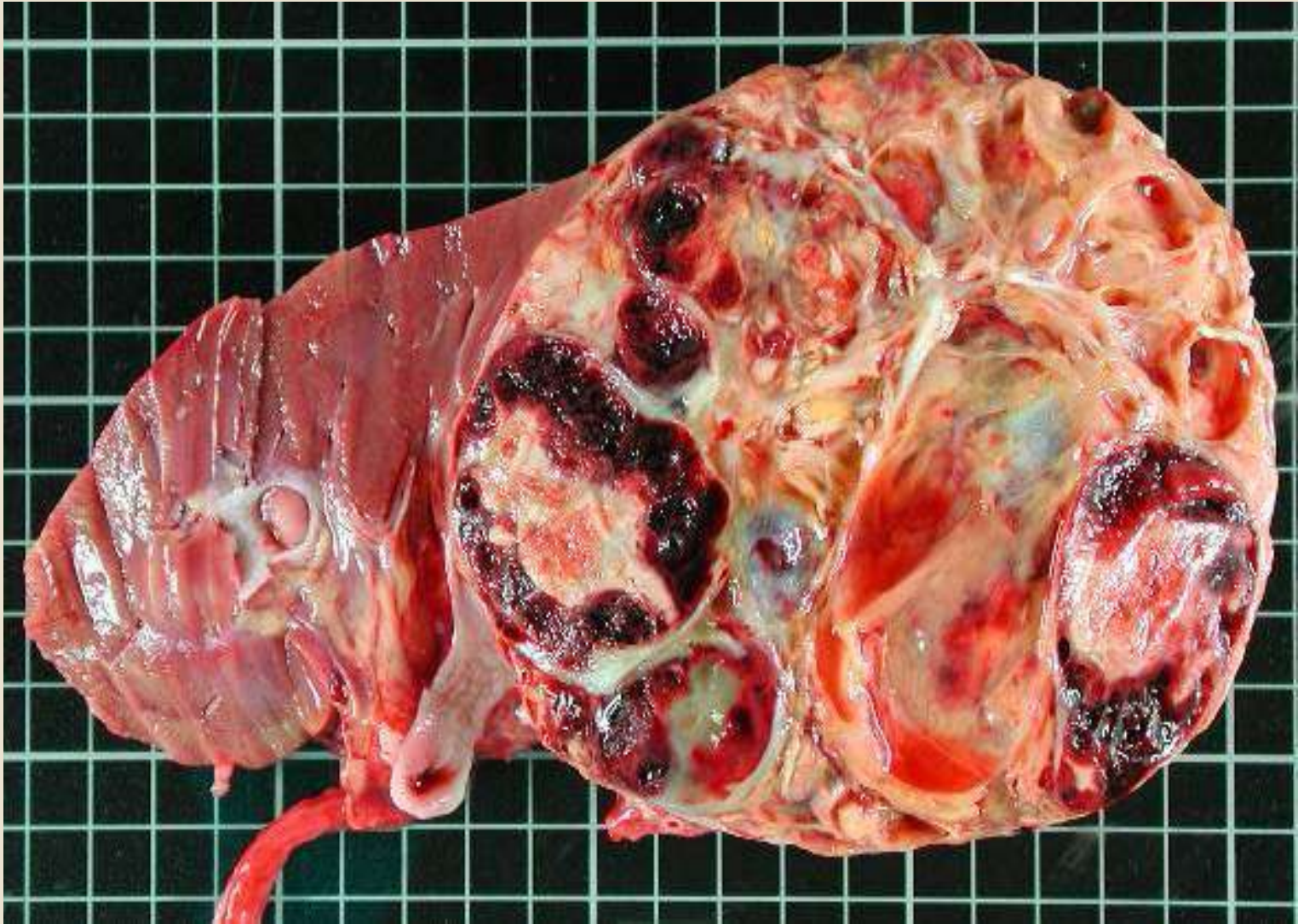Highly aggressive (< 6 months)

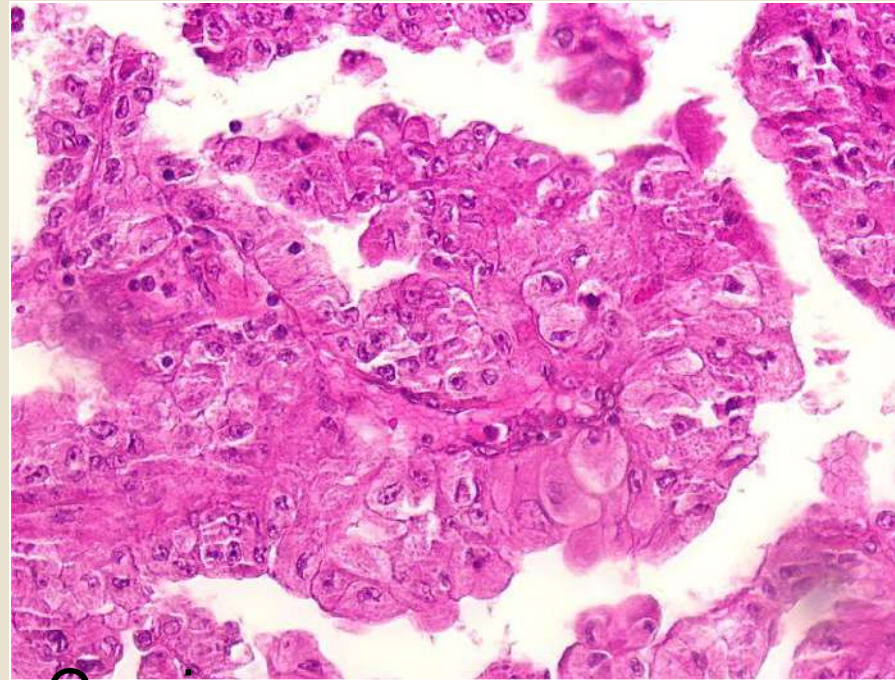
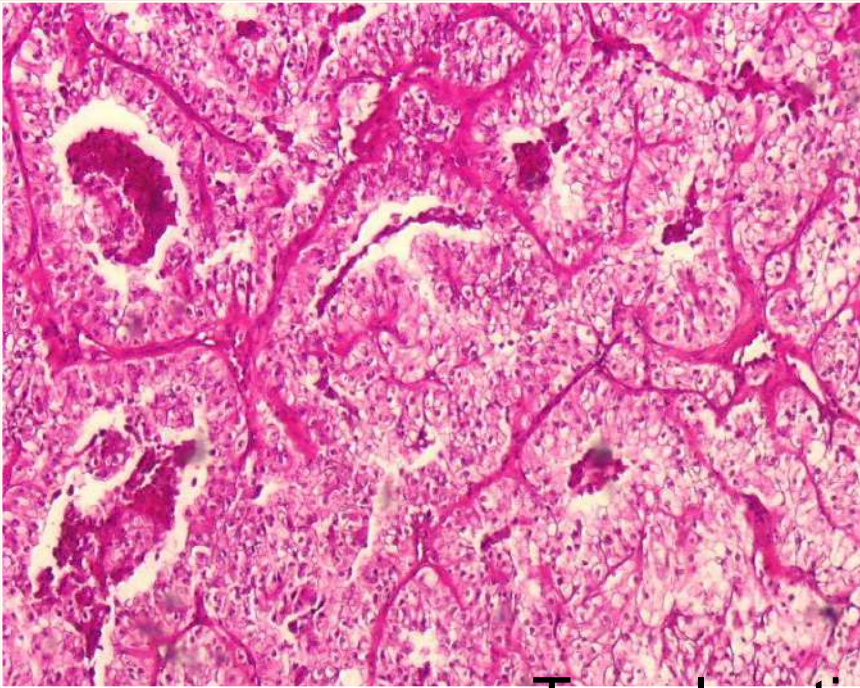
Renal cell tumours

Clear cell renal cell carcinoma	8310/3
Multilocular cystic renal neoplasm of low malignant potential	8316/1
Papillary renal cell carcinoma	8255/1
Hereditary leiomyomatosis and renal cell carcinoma (HLRCC)-associated renal cell carcinoma	8311/3*
Chromophobe renal cell carcinoma	8317/3
Collecting duct carcinoma	8319/3
Renal medullary carcinoma	8510/3
MiT Family translocation carcinomas	8311/3
Succinate dehydrogenase (SDH)-deficient renal carcinoma	8312/3
Mucinous tubular and spindle cell carcinoma	8480/3
Tubulocystic renal cell carcinoma	8316/3
Acquired cystic disease associated renal cell carcinoma	8316/3
Clear cell papillary renal cell carcinoma	8323/1
Renal cell carcinoma, unclassified	8312/3
Papillary adenoma	8260/0
Oncocytoma	8290/0

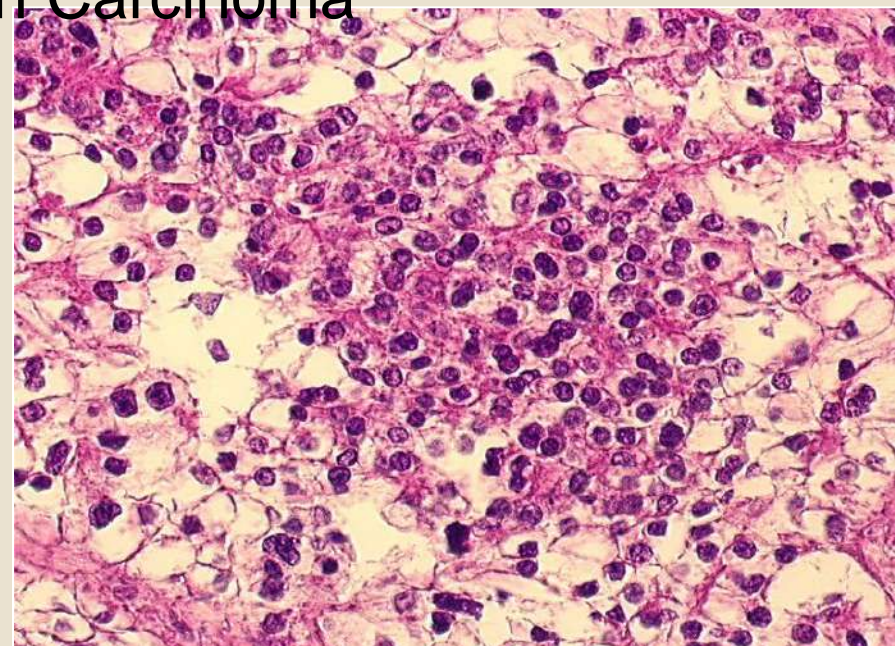
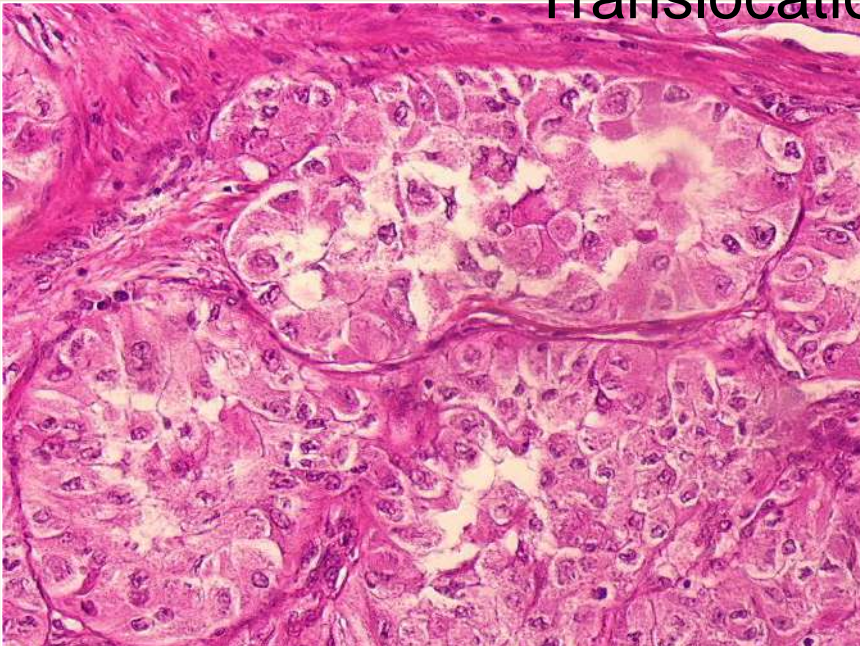


MIT Family Translocation Carcinoma





Translocation Carcinoma



Translocation Carcinoma

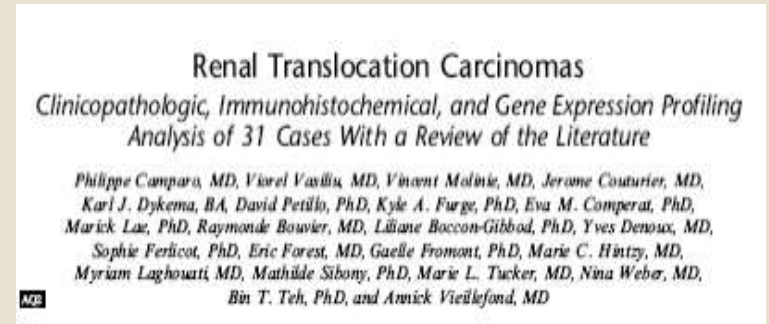Mean age : 23

Sex ratio : 1,7/2,3

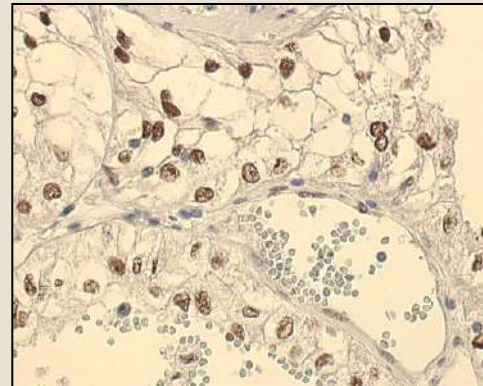
N+ : 40-70%

Translocation involving MiTF
TFE3 (Xp11), TFEB (6p11)
Various fusion genes


CK7- CD10+ AMACR+
Melanocytic markers



Am J Surg Nov 2007



TFE3

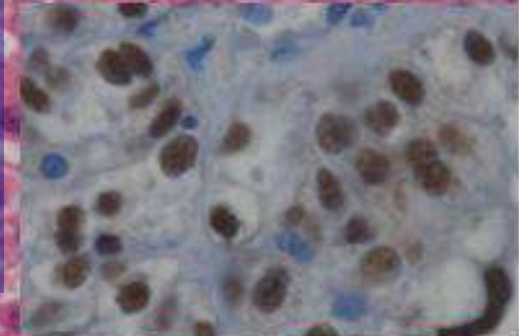


Translocation Carcinoma

A histological slide showing a dense population of atypical cells with large, hyperchromatic nuclei and prominent nucleoli. The cells are arranged in nests and cords, separated by thin layers of connective tissue. The overall appearance is that of a malignant neoplasm. A blue box at the top center contains the title 'Translocation Carcinoma'. A larger blue box at the bottom left contains clinical and prognostic information. A smaller inset image at the bottom right shows a higher magnification of the cellular details.

Young adults
Atypical histology

Prognosis still to be determined
Depend on fusion gene

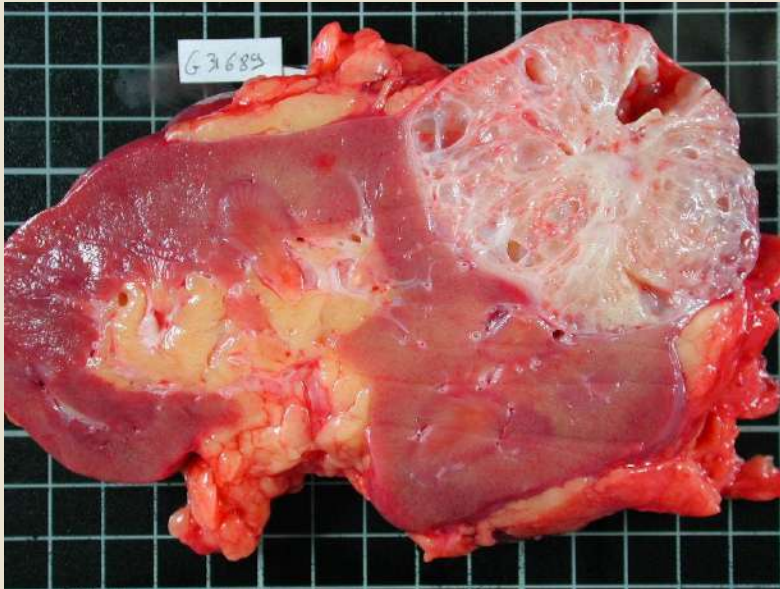

Renal cell tumours

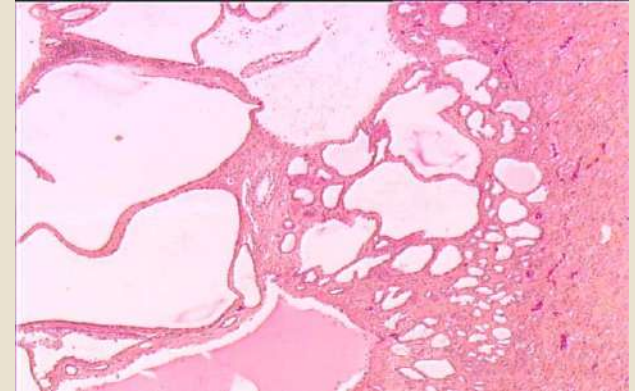
Clear cell renal cell carcinoma	8310/3
Multilocular cystic renal neoplasm of low malignant potential	8316/1
Papillary renal cell carcinoma	8255/1
Hereditary leiomyomatosis and renal cell carcinoma (HLRCC)-associated renal cell carcinoma	8311/3*
Chromophobe renal cell carcinoma	8317/3
Collecting duct carcinoma	8319/3
Renal medullary carcinoma	8510/3
MiT Family translocation carcinomas	8311/3
Succinate dehydrogenase (SDH)-deficient renal carcinoma	8312/3
Mucinous tubular and spindle cell carcinoma	8480/3
Tubulocystic renal cell carcinoma	8316/3
Acquired cystic disease associated renal cell carcinoma	8316/3
Clear cell papillary renal cell carcinoma	8323/1
Renal cell carcinoma, unclassified	8312/3
Papillary adenoma	8260/0
Oncocytoma	8290/0



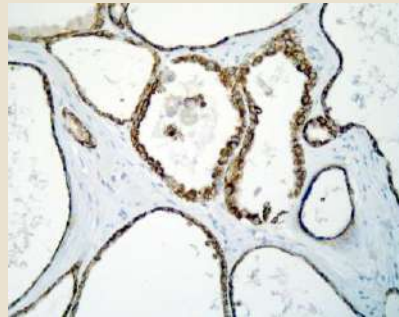
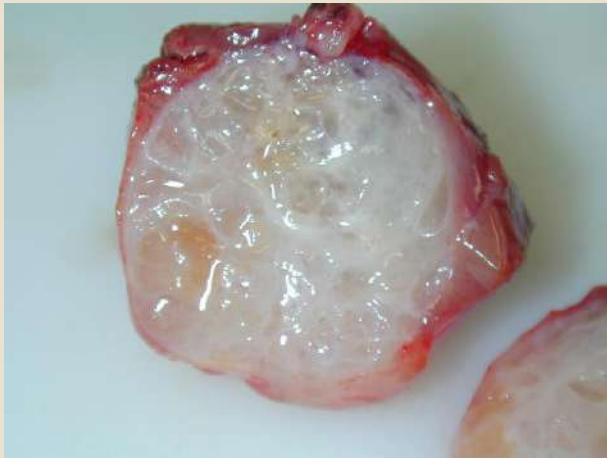Tubulo-cystic carcinoma (low grade)



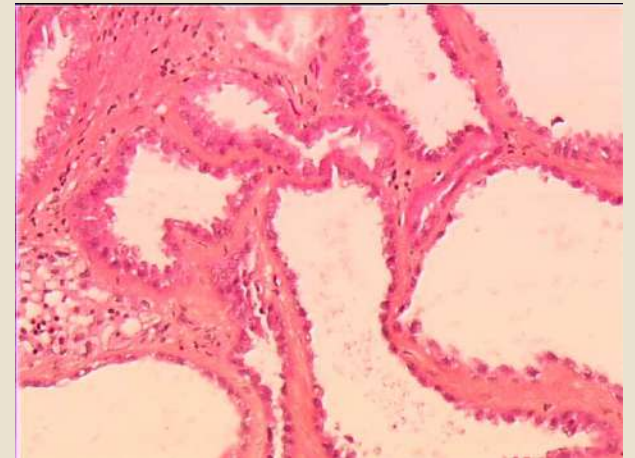
Small
spongiform
tumours



Dilated tubules lined by a single layer
of hobnail cells Low Fuhrman grade




CK7 +
AMACR +
CD10+



Renal cell tumours

Clear cell renal cell carcinoma	8310/3
Multilocular cystic renal neoplasm of low malignant potential	8316/1
Papillary renal cell carcinoma	8255/1
Hereditary leiomyomatosis and renal cell carcinoma (HLRCC)-associated renal cell carcinoma	8311/3*
Chromophobe renal cell carcinoma	8317/3
Collecting duct carcinoma	8319/3
Renal medullary carcinoma	8510/3
MiT Family translocation carcinomas	8311/3
Succinate dehydrogenase (SDH)-deficient renal carcinoma	8312/3
Mucinous tubular and spindle cell carcinoma	8480/3
Tubulocystic renal cell carcinoma	8316/3
Acquired cystic disease associated renal cell carcinoma	8316/3
Clear cell papillary renal cell carcinoma	8323/1
Renal cell carcinoma, unclassified	8312/3
Papillary adenoma	8260/0
Oncocytoma	8290/0



Acquired cystic disease associated renal cell carcinomas

Spectrum of Epithelial Neoplasms in End-Stage Renal Disease

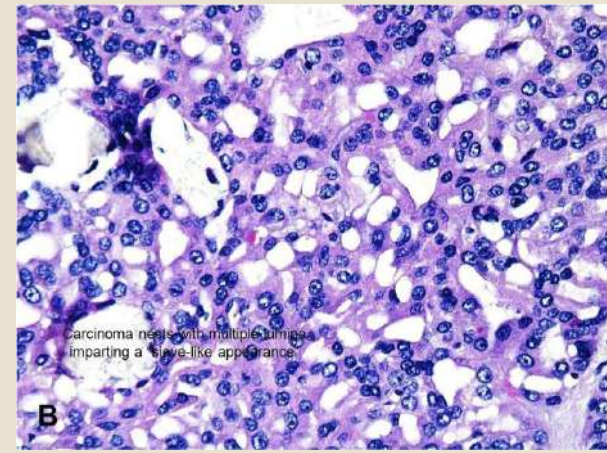
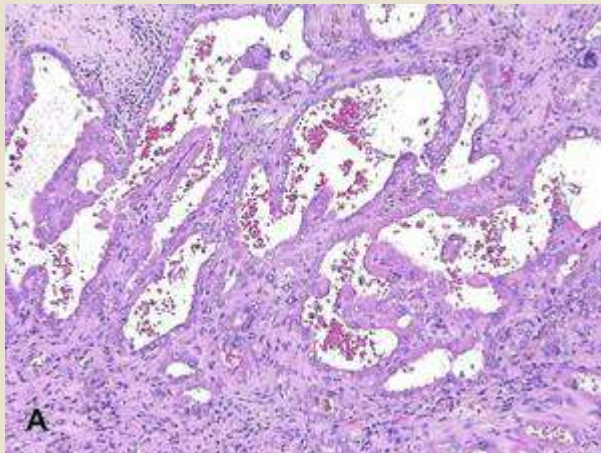
An Experience From 66 Tumor-Bearing Kidneys With Emphasis on Histologic Patterns Distinct From Those in Sporadic Adult Renal Neoplasia

Satish K. Tickoo, MD, Mariza N. dePeralta-Venturina, MD,†† Lara R. Harik, MD,* Heath D. Worcester, MD,§ Mohamed E. Salama, MD,‡ Andrew N. Young, MD,§ Holger Moch, MD,|| and Mahul B. Amin, MD§*

>30% carcinomas in end-stage renal disease

Multifocal

Bilateral 1/3



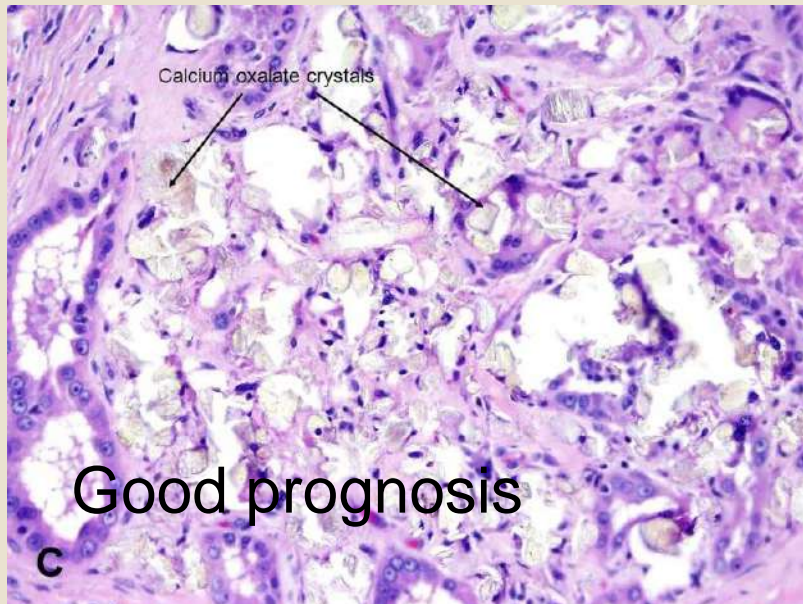
Acquired cystic disease associated renal cell carcinomas

Spectrum of Epithelial Neoplasms in End-Stage Renal Disease

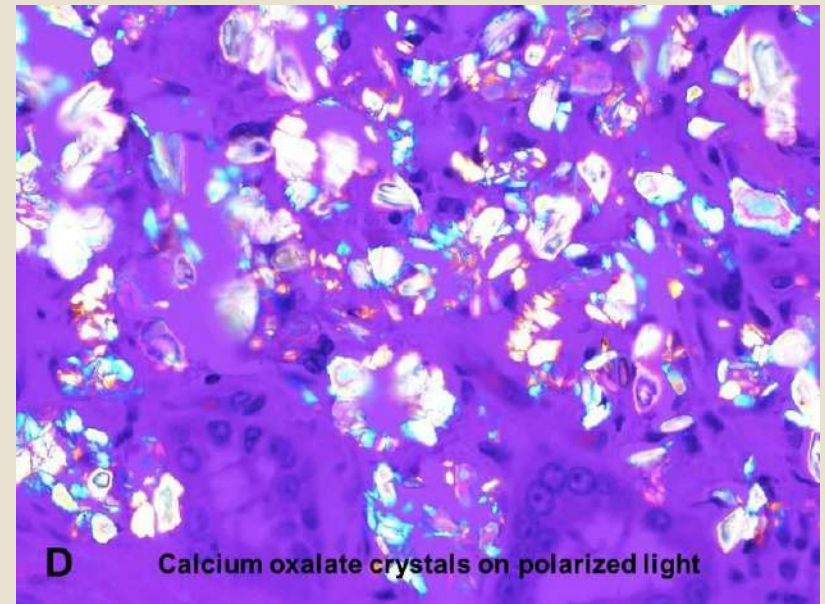
An Experience From 66 Tumor-Bearing Kidneys With Emphasis on Histologic Patterns Distinct From Those in Sporadic Adult Renal Neoplasia

Satish K. Tickoo, MD, Mariza N. dePeralta-Venturina, MD,†† Lara R. Harik, MD,* Heath D. Worcester, MD,§ Mohamed E. Salama, MD,‡ Andrew N. Young, MD,§ Holger Moch, MD,|| and Mahul B. Amin, MD§*

Polymorphic irregular glandular appearance
Calcium Oxalate crystals



Good prognosis



Clear Cell Papillary Renal Cell Carcinomas

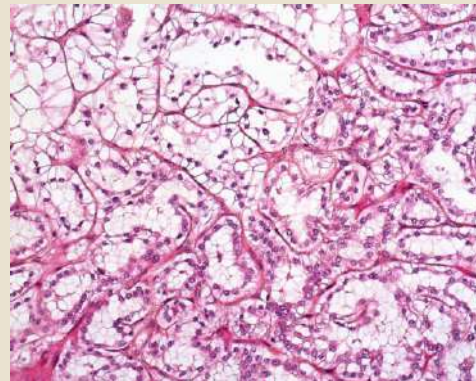
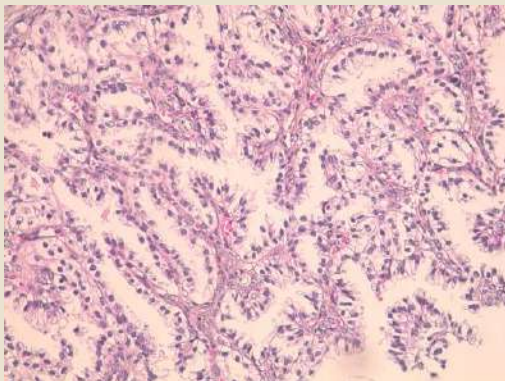
Mean age : 58.1

Sex ratio : 2,3/1

30% end-stage renal disease

60% : normal kidney

Tubular or papillary architecture, compact or cystic



Clear cells
Small size
Central nucleus

Spectrum of Epithelial Neoplasms in End-Stage
Renal Disease

*An Experience From 66 Tumor-Bearing Kidneys With Emphasis on
Histologic Patterns Distinct From Those in Sporadic Adult
Renal Neoplasia*

Satish K. Tickoo, MD, Mariza N. dePeralta-Venturina, MD,†† Lara R. Harik, MD,*
Heath D. Worcester, MD,§ Mohamed E. Salama, MD,‡ Andrew N. Young, MD,§ Holger Moch, MD,||
and Mahul B. Amin, MD§*

Clear Cell Papillary Renal Cell Carcinomas

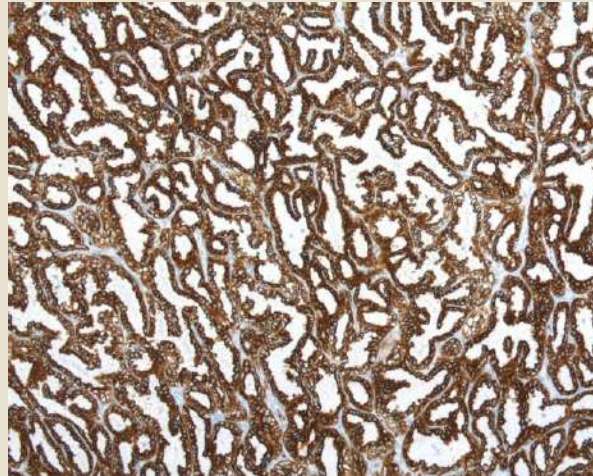
CK7+

Vim +

CA IX +

CD10-

AMACR -



No cytogenetic
abnormalities

pT1

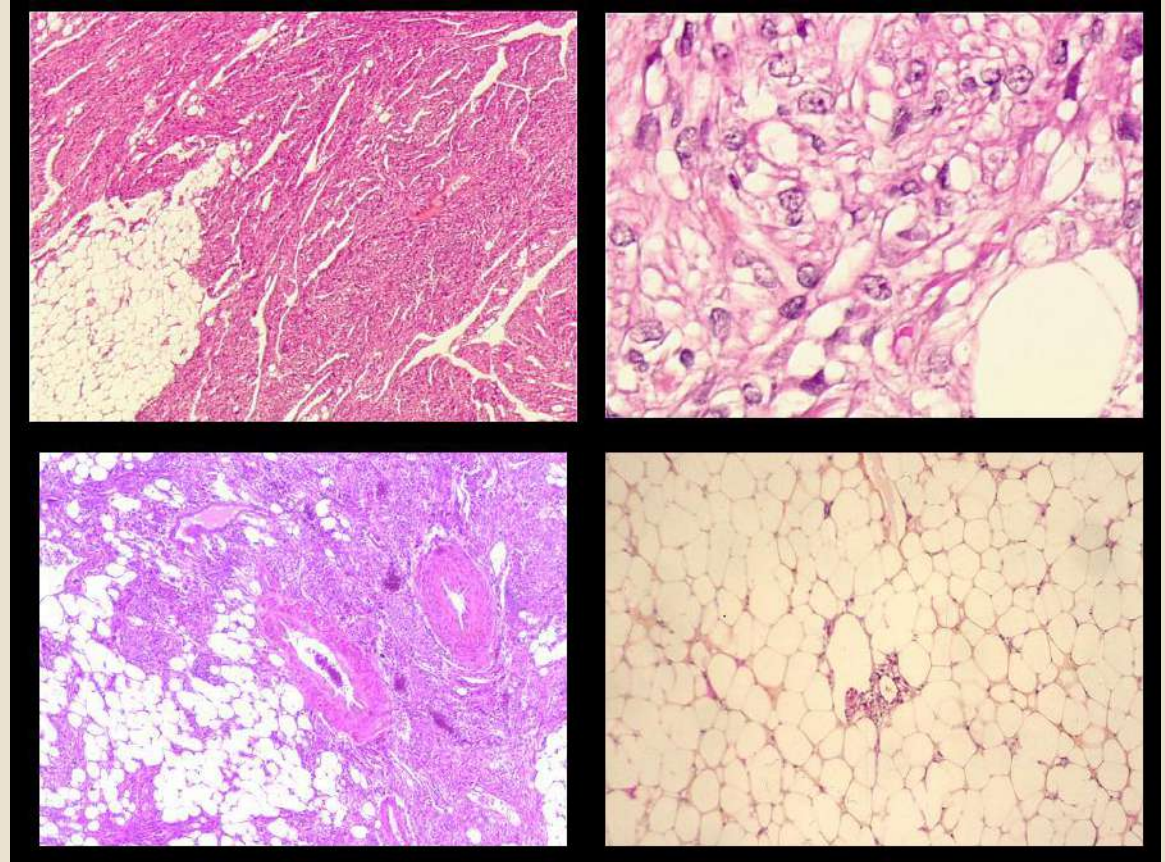
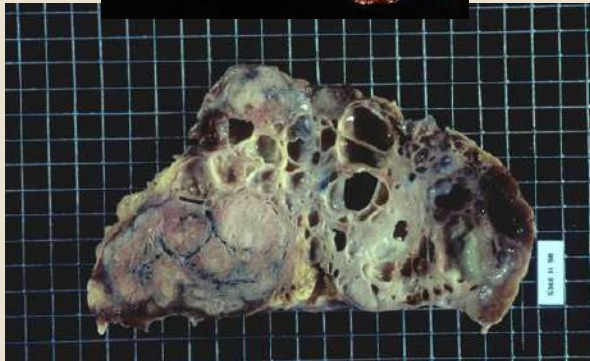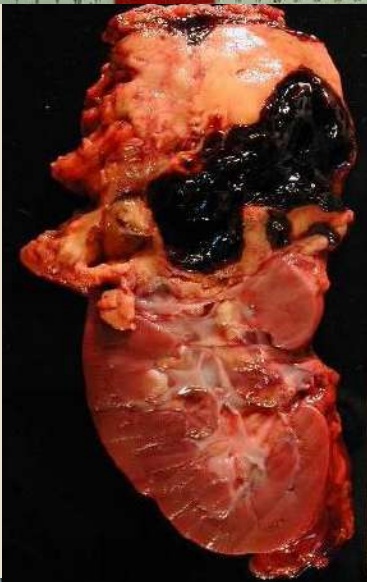
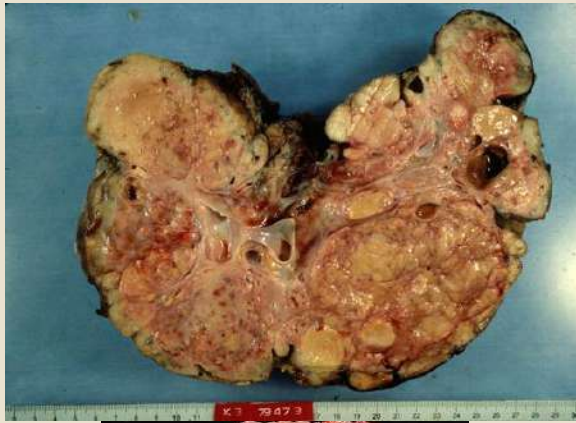Low Fuhrman grade

No follow up

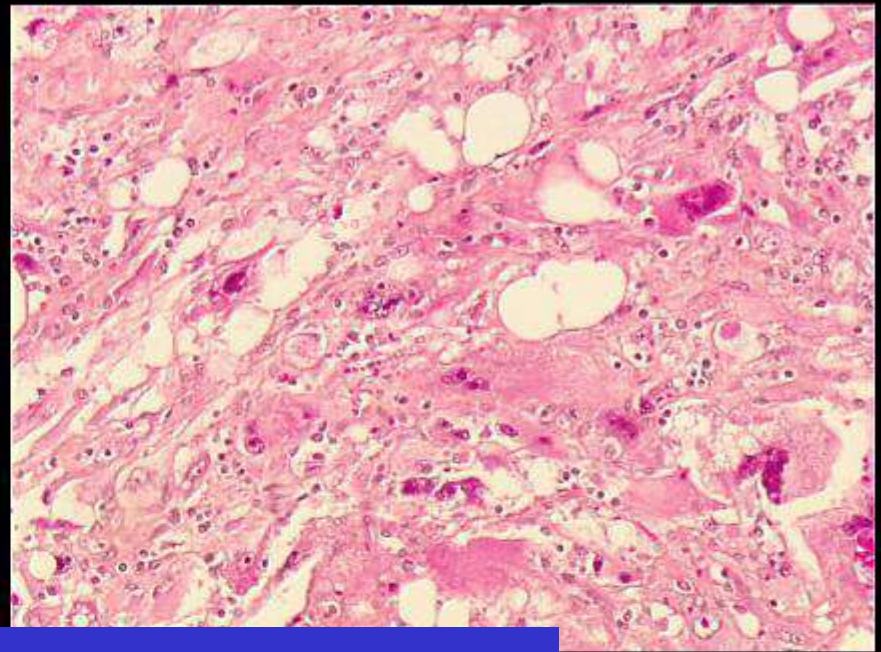
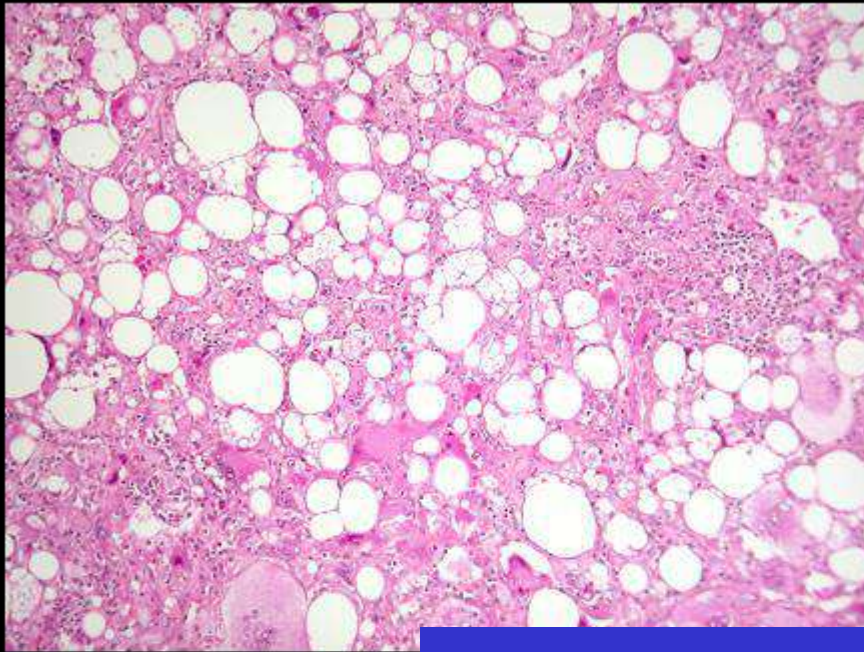
Clear and Papillary RCC Immunohistochemistry

Histologic subtype	EMA	CD10	Vim	Ca9	CK7	AMACR
Clear Cell	+	+	+	+	-	-
Tubulo papillary Carcinoma	-	-	-	-	+	+
Mucinous tubular and spindle cell carcinoma	-	-	-	-	+	+
Translocation Carcinoma	-	+	+	-	-	+
Clear Cell with papillary features	+	+	+	+	-	-

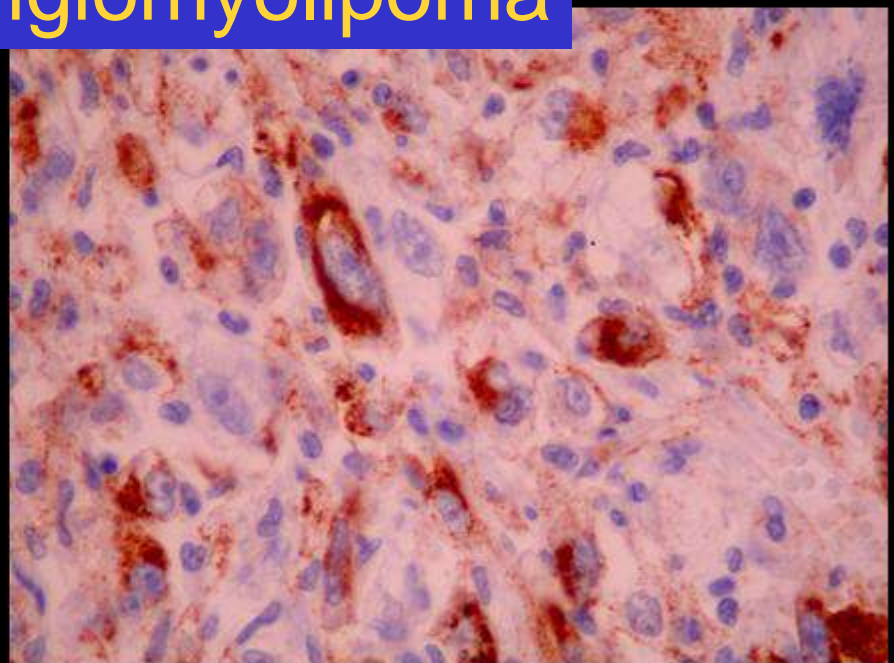
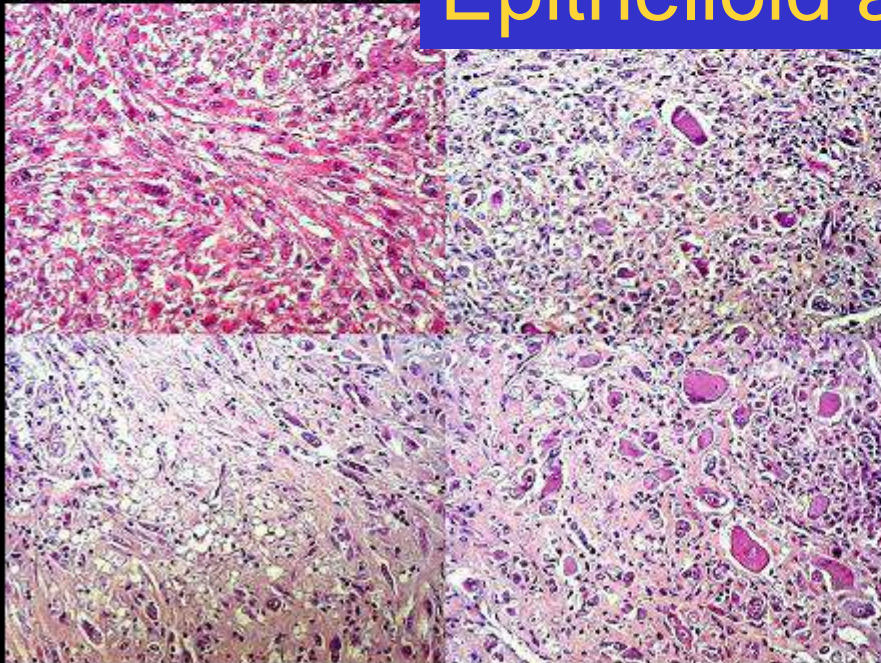
Angiomyolipoma (TSC)



Vim, AML, Melanocytic markers



Epithelioid angiomyolipoma



Epithelioid angiomyolipoma

Variant described in 1997 and 1998.

Association with TSC (like AML)

Fusiform and epithelioid cell proliferation (atypical and suspicious for high grade RCC)

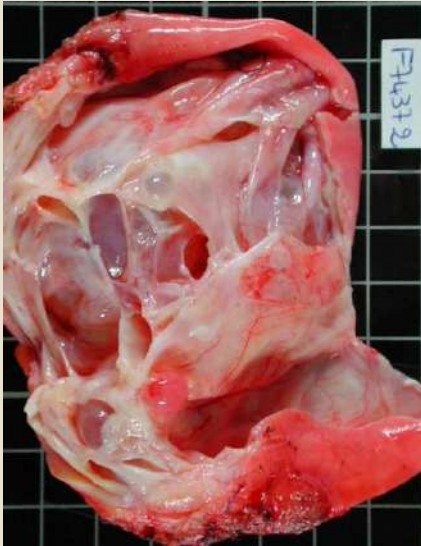No CK expression (DD sarcomatoid carcinoma)

Positivity for HMB45 (and muscular markers MLA)

Lymph node and visceral metastasis in about 1/3 cases.

Malignant Pecoma

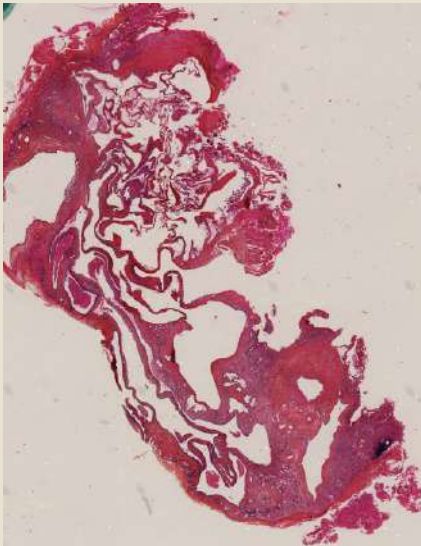
Cystic nephroma



Female predominance

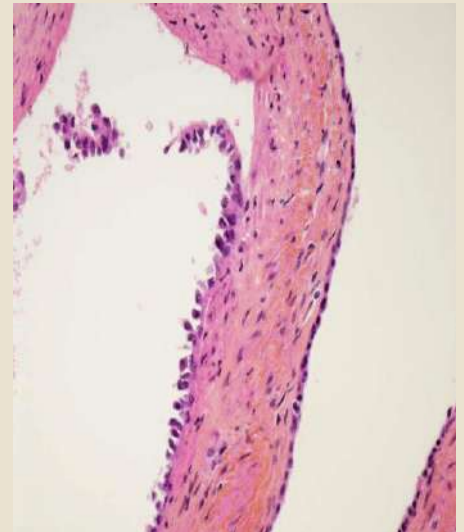
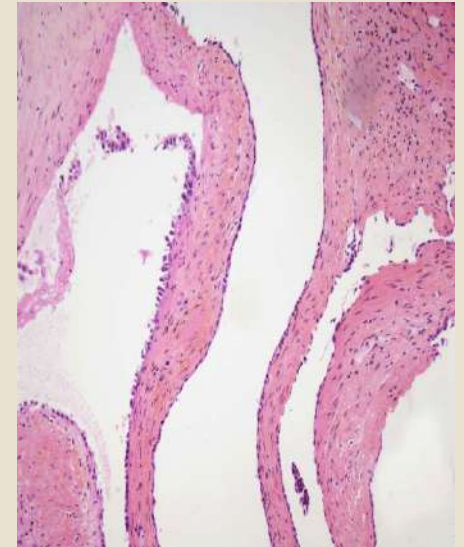
Multilocular cysts (>4 cm)

Unistratified cubic or flat epithelium with hobnail pattern



Fibrous septa with some residual renal tubules poorly cellular

Vimentine+,
Actine+, Desmine+
ER+, PR+, CD10+



Mixed epithelial and stromal tumours

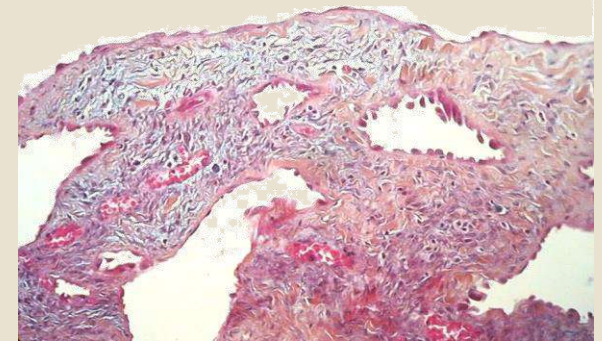
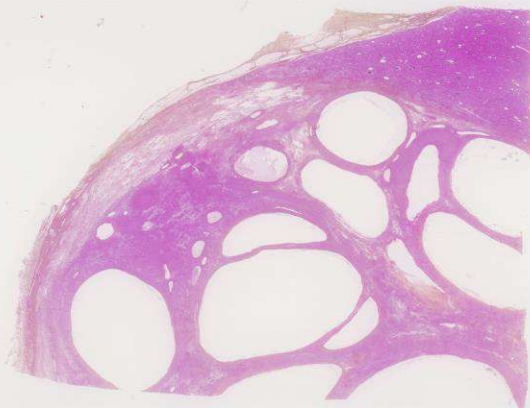
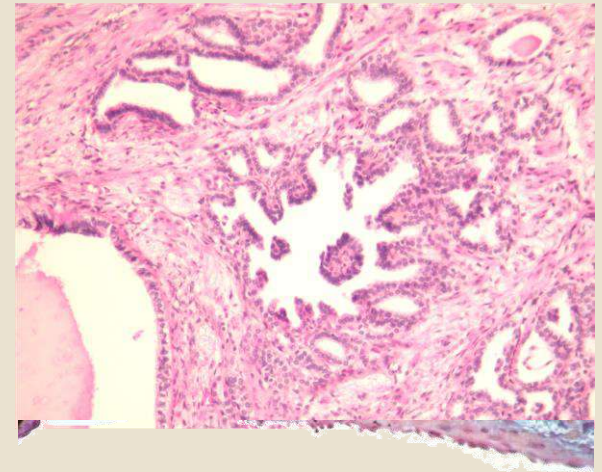
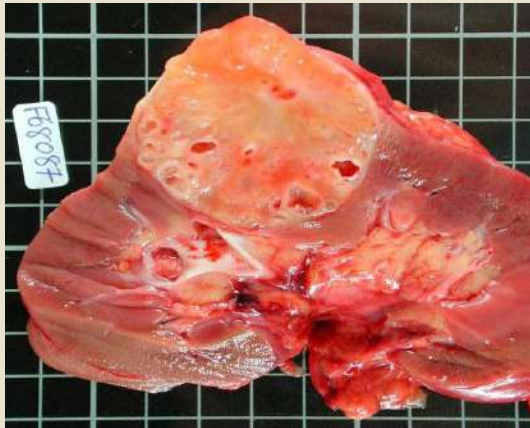
Female predominance

Solid +/- small cysts

Unistratified cubic or flat epithelium with hobnail and phylloid like patterns

Ovarian like stroma residual renal tubules

Vimentine+,
Actine+, Desmine+
ER+, PR+, CD10+
Stromal cells inhibine +



REST

Cystic Nephroma and Mixed Epithelial and Stromal Tumor of Kidney: A Detailed Clinicopathologic Analysis of 34 Cases and Proposal for Renal Epithelial and Stromal Tumor (REST) as a Unifying Term

Julia Turbiner, MD,* Mahul B. Amin, MD,† Peter A. Humphrey, MD,‡ John R. Srigley, MD,§
Laurence De Leval, MD,|| Anuradha Radhakrishnan, MD,† and Esther Oliva, MD*

Am J Surg Pathol 2007

Benign tumours

Sex ratio : 1:6 Mean age 50 y

Well circumscribed

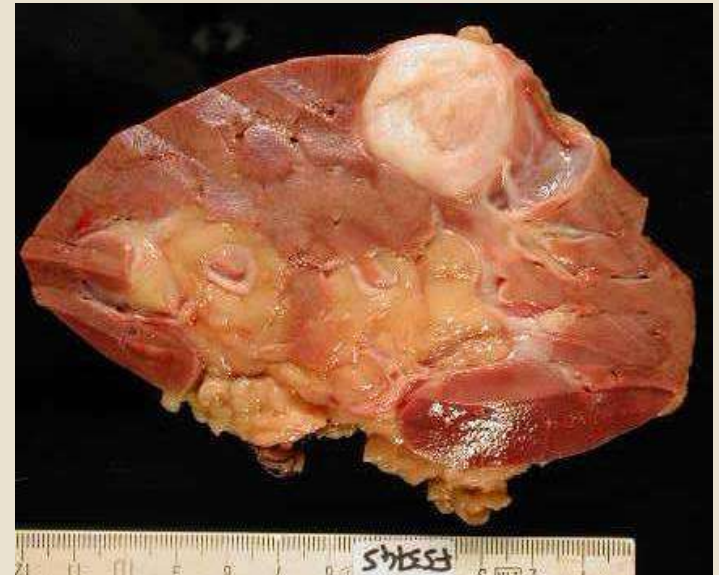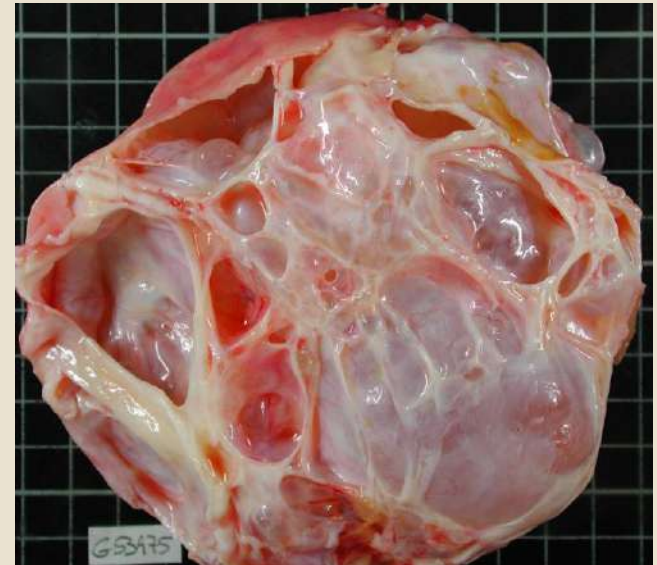Epithelial and stromal components of variable importance

Stroma actine +, ER +et PR+

Cystic Nephroma and Mixed Epithelial and Stromal Tumour of the Kidney: Opposite Ends of the Spectrum of the Same Entity?

Rodolfo Montironi^{a,*}, Roberta Mazzucchelli^a, Antonio Lopez-Beltran^b,
Guido Martignoni^f, Liang Cheng^d, Francesco Montorsi^e, Marina Scarpelli^a

Eur Urol 2007



Differential diagnoses of REST

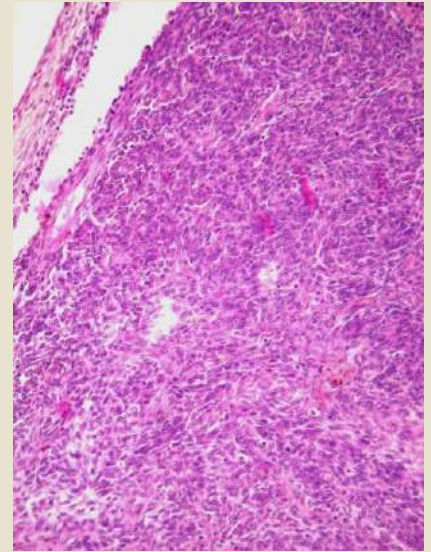
Solid tumours with cystic areas

Synovial sarcoma atypia, mitoses

CD99 + , BCl2 +, actine -, desmine -, translocation t (X;18)

Angiomyolipoma with epithelial cysts

Oncocytomas

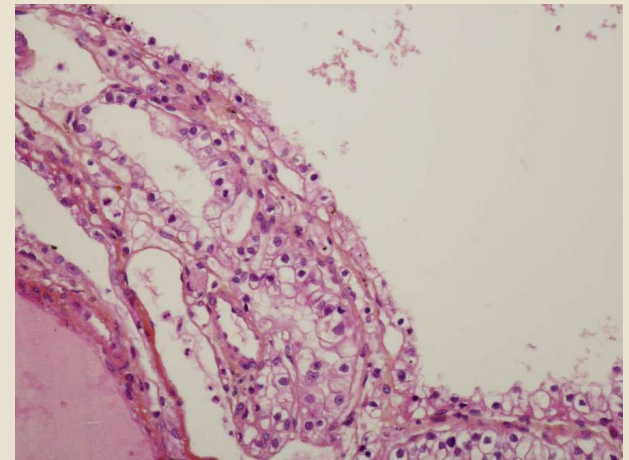


Cystic tumours

Multilocular (cystic) carcinoma

Cystic nephroblastoma (theoretical <2 y)

Tubulo cystoc carcinomas



	Histochimie	IHC	cytogenetique	Molecular biology
CCC		EMA + RCC + CAIX + CD10 + vimentine + CK7 +/-, racémase +/- CD117 -	Délétion 3p-	Mutation <i>VHL</i> (3p25-26) dans les formes familiales et dans plus de la moitié des cas des formes sporadiques
Ca pap		CK7 +, CD10 + racémase + vimentine + EMA + RCC + CAIX - CD117-	Types 1 & 2 : Trisomies 7, 17, perte de l'Y, amplification 8q	- Type 1 : mutation de <i>c-met</i> (7q31-32) (formes familiales et sporadiques) - Type 2 : mutation de <i>FH</i> en 1q42 (forme familiale) ou amplification de <i>Myc</i> en 8q (forme sporadique)
Ca chromo	Hale diffus microvésiculaire	CK7 + en cadre CD10 +/- racémase - EMA + vimentine - CD117 + CaIX-	Monosomie chromosomique - 3p, -5q, -17p, -17q	
onco	Hale apical	CK7 - ou focal CD10 +/- EMA + vimentine -	Délétion 1, 3, 7, 14, X, Y, ou pas d'anomalies	

	Colo spe	IHC	cytogenetique
Carcinome avec translocation TFE3 ou TFEB		CK7-, CD10 + racémase + vimentine + RCC + TFE3 + ou TFEB +	t(X;1)(p11.2;q21) : gène de fusion PRCC-TFE3 t(X;17)(p11.2;q25) : gène de fusion ASPL-TFE3 t(6 ;1)(p21;q12) : translocation alpha-TFEB
Carcinome tubulo-mucineux	Bleu Alcian	CK7+, CD10 – racémase +/-vimentine + RCC +	Anomalies variées : gains ou pertes chromosomiques
Carcinome des tubes collecteurs		CK7 -, KL1 + EMA+ vimentine + Ulex + CK20 +	
Tumeur mixte épithéliale et stromale		Cellules stroma : vimentine +, actine et desmine +, RO et RP + dans 75% des cas	

Renal papillary unclassified represent
5% of renal tumors

Other lesions are not rare

They are exceptional...